

The Figure-of-Four View to Evaluate ACL Injury

Samir G. Tejwani, MD, BSE*

Robert G. Marx, MD, MSc, FRCS(C)†

Russell F. Warren, MD†

Standard arthroscopic assessment of the anterior cruciate ligament (ACL) injury through an anterior view can be sub-optimal for evaluation of the femoral origin, particularly the posterior component. The figure-of-four view provides increased exposure to the posterolateral aspect of the intercondylar notch, thereby facilitating diagnosis of proximal ACL injury and avulsions of the ACL origin.

Diagnostic arthroscopy is the gold standard for diagnosing ACL injury, particularly when distinguishing between partial and complete ACL rupture. Arthroscopic assessment of the ACL can be difficult, particularly in cases of proximal tears or avulsions from the femoral insertion. The most commonly used arthroscopic approach to the ACL requires a 30° scope with

the knee flexed 30°-90°.¹ Looking straight on through an anterolateral portal, the distal ACL can be visualized at its tibial insertion. The origin of the ACL can be appreciated by looking at the medial aspect of the lateral femoral condyle, although it often can be difficult to visualize with the knee flexed at 90° without varus or valgus stress. A patient with a proximal ACL tear or an avulsion of the femoral origin of the ACL who is being examined with this technique may appear to be without injury, particularly if the synovium is intact. Visualization of the distal ACL will reveal intact fibers at its insertion into the interspinous area of the tibia, while suboptimal visualization of the origin of the ACL can preclude the discovery of proximal ACL injury.

A vertically oriented septum or an intact synovial sleeve can mask a proximal ligament injury. If a vertical septum is present, it should be resected

arthroscopically and the ACL should be probed to note collagen organization as well as tension with an anteriorly directed force. Partial tears or injuries that are healing are important to note as the ligament may have retained function. The pivot shift test is particularly valuable in this situation because a positive test indicates the ligament is not performing adequately, despite what is seen arthroscopically.

This article describes a figure-of-four patient position during arthroscopy, which we routinely use to visualize the posterolateral aspect of the intercondylar notch. In this position, the lateral side of the knee and the ACL are placed

Share Your "Pearls"

Do you have a technique or tip to share?

ORTHOPEDICS wants to hear from you. Send submissions to Steven F. Harwin, MD, % ORTHOPEDICS, 6900 Grove Rd, Thorofare, NJ 08086; or contact Mary Jerrell, ELS, Executive Editor, at (856) 848-1000; fax (856) 853-5991; e-mail mjerrell@slackinc.com; or www.slackinc.com/ortho.htm.

*From the *Department of Orthopedic Surgery, University of California Los Angeles, Center for Health Sciences, Los Angeles, Calif, and the †Sports Medicine and Shoulder Service, Hospital for Special Surgery, New York, NY.*

Dr Marx is supported by an American Academy of Orthopaedic Surgeons Health Services Research Fellowship and a Royal College of Physicians and Surgeons of Canada Detweiler Traveling Fellowship.

Reprint requests: Robert G. Marx, MD, MSc, FRCS(C), Sports Medicine and Shoulder Service, Hospital for Special Surgery, 535 E 70th St, New York, NY 10021.

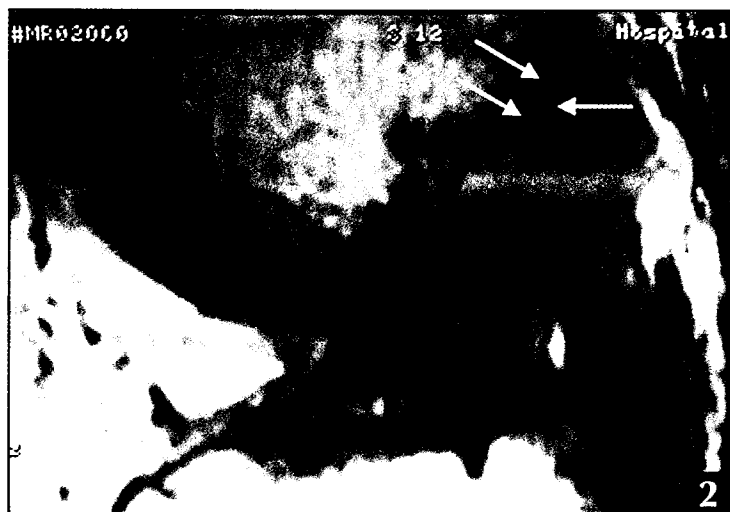
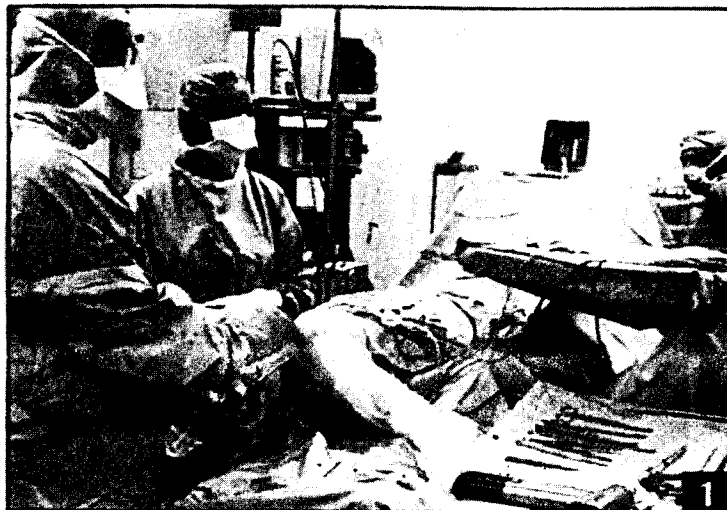

Figure 1: Figure-of-four patient position. Figure 2: Sagittal MRI of the right knee demonstrating a tear of the proximal ACL, with residual synovial attachment to the posterolateral aspect of the intercondylar notch (arrows).

under tension. This allows us to clearly view the proximal fibers and origin of the ACL. The position is most useful in patients who have clinical and magnetic resonance imaging (MRI) evidence of ACL insufficiency but who have a normal appearing ligament when viewed anteriorly from the notch.

ARTHROSCOPIC TECHNIQUE

The patient is placed supine on the operating room table and draped in the standard fashion. Anterolateral and anteromedial portals are created for the 30° arthroscope and probe, respectively. The ipsilateral foot is placed on the contralateral knee, thereby creating the figure-of-four position (Figure 1). The arthroscope is placed in the lateral compartment and advanced into the intercondylar notch. The probe is placed in the intercondylar notch and is used to pull the ACL medially to view the proximal fibers and the femoral origin of the ACL.

CASE REPORT

A 27-year-old professional football player presented with a knee injury that occurred while blocking. Physical examination revealed slightly increased anterior translation, with a soft end-point. He had a grade 3 medial collateral ligament injury that had healed in the 6 weeks prior to surgery.

Anteroposterior, lateral, and tunnel radiographs of the involved knee were unremarkable. Magnetic resonance imaging of the knee at the time of injury demonstrated a proximal ACL tear (Figure 2). Examination under anesthesia revealed a positive (grade 1B) Lachman test and a 1+ pivot shift test.

During diagnostic arthroscopy, anteromedial and anterolateral portals were created, and after identifying a normal appearing but mildly loose ACL (Figure 3), the patient was placed in the figure-of-four position. With the arthroscope inserted in the lateral aspect of the intercondylar notch and a probe on the ACL, we were able to assess the posterior component of the ACL, which was completely ruptured (Figures 4 and 5). Arthroscopic reconstruction of the ACL was performed with patellar tendon autograft.

DISCUSSION

The most common site of rupture of the ACL is the proximal ligament.²⁻⁴ Although a number of authors have reported avulsions of the femoral insertion of the ACL that were diagnosed initially by "notch" or "tunnel" radiographs,⁵⁻⁷ proximal ACL tears are not reliably identified by these tests. The Lachman and pivot shift tests performed under anesthesia are the most sensitive physical examination tools for diagnosing ACL injury.⁸ In general, correlation with a meticulous arthroscopic examination of the knee will yield a definitive diagnosis.

Arthroscopy of the ACL-injured knee using a 30° arthroscope and probe is directed at assessing fiber orientation, tension, and attachment in the proximal, middle, and distal ligament substance. With the arthroscope inserted in an anterolateral portal, an anterior view of the intercondylar notch can be obtained, thus providing a good view of the anteromedial bundle of the ACL. To assess the posterolateral aspect of the ACL, we prefer to place the patient in the figure-of-four position. With the arthroscope and probe remaining in their respective portals, assessment of proximal ACL fiber orientation, tension, and attachment can be performed.

Our patient had a positive pivot shift test on examination under anesthesia. Subsequent arthroscopic examination through an anterior view revealed normally oriented fibers (Figure 3). When probing for tension and attachment distally, the ACL was minimally lax with an intact tibial insertion. With the patient in the figure-of-four position, significant laxity of the proximal substance was appreciated with probing, which correlated with the MRI findings of proximal ligament disruption.

Further probing of the proximal ACL origin was performed in the figure-of-four position, and detachment proximally was readily apparent (Figures 4 and 5). This was less obvious in the anterior view due to the residual proxi-

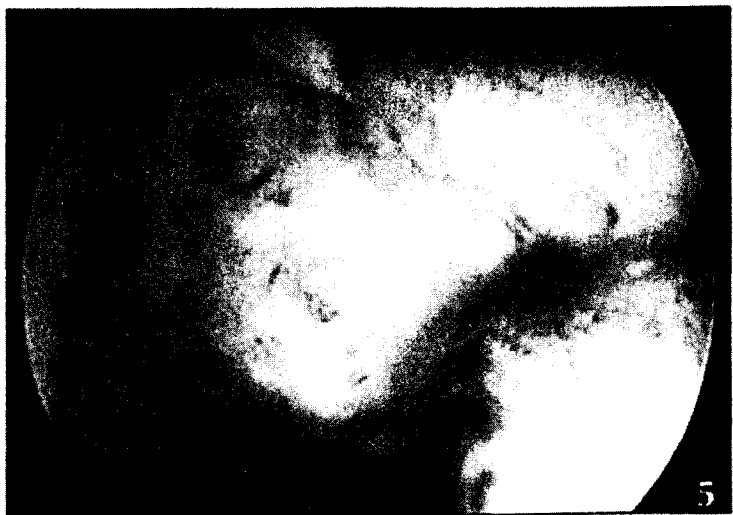
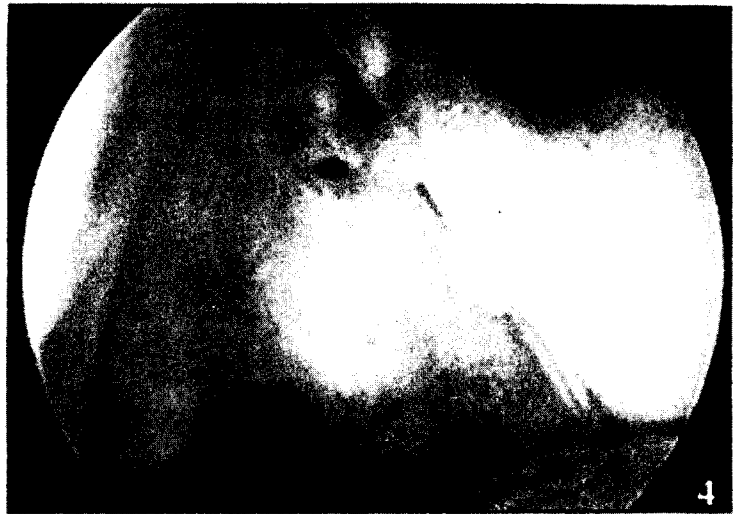
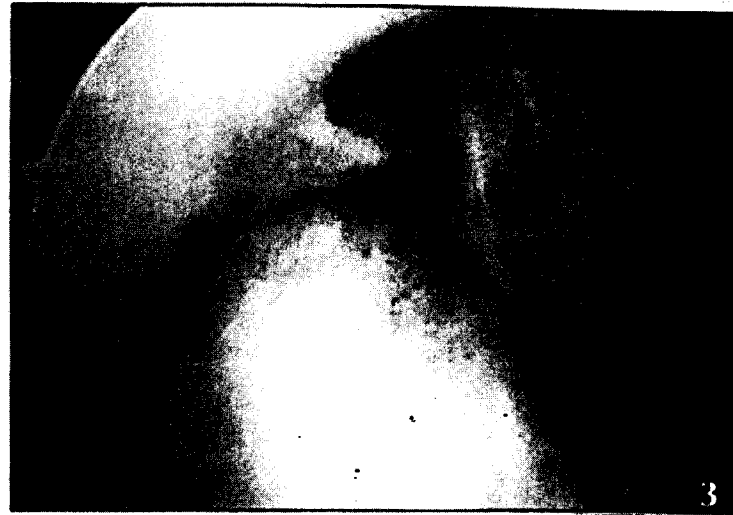Figure 3: The midsubstance of the ACL appears normal. Figure 4: Disruption of the proximal ACL, before probing, is appreciated with the patient in the figure-of-four position. Figure 5: After probing, a complete tear of the proximal ACL is visualized with the patient in the figure-of-four position.

Take Home "Pearl"...

"The figure-of-four view can be performed quickly through standard anterolateral and anteromedial portals, and it significantly improves exposure to the posterolateral aspect of the intercondylar notch."

mal synovial attachment of the ACL to the lateral intercondylar wall.

The figure-of-four patient position was beneficial in determining the amount of proximal ligament disruption, which was masked by the residual synovial attachments. At times, the ACL is reattached to the posterior cruciate ligament and not to the lateral wall, thereby producing an empty wall sign with a vertical strut.⁹ In this case, the figure-of-four position also is necessary to adequately assess the posterior femoral attachment, which is typically disrupted.

The figure-of-four view is useful in the comprehensive arthroscopic evalua-

tion of the ACL. It can be performed quickly through standard anterolateral and anteromedial portals, and it significantly improves exposure to the posterolateral aspect of the intercondylar notch. We recommend using the figure-of-four view as an adjunct to the standard examination of the ACL, thereby facilitating the diagnosis of proximal ACL injuries and avulsions of ACL origin.

REFERENCES

1. Scott WN, Insall JN, Kelly MA. Arthroscopy and meniscectomy: surgical approaches, anatomy and techniques. In: Insall JN, Windsor RE, Kelly MA, Scott WN, Aglietti P, eds. *Surgery of the Knee*. 2nd ed. New York, NY: Churchill

Livingstone; 1993:165-215.

2. Higgins RW, Steadman JR. Anterior cruciate ligament repairs in world class skiers. *Am J Sports Med*. 1987; 15:439-447.

3. Paessler HH, Deneke J, Dahners LE. Augmented repair and early mobilization of acute anterior cruciate ligament injuries. *Am J Sports Med*. 1992; 20:667-674.

4. Sherman MF, Lieber L, Bonamo JR, Podesta L, Reiter I. The long-term follow-up of primary anterior cruciate ligament repair. Defining a rationale for augmentation. *Am J Sports Med*. 1991; 19:243-255.

5. Eady JL, Cardenas CD, Sopa D. Avulsion of the femoral attachment of the anterior cruciate ligament in a 7-year-old child. A case report. *J Bone Joint Surg Am*. 1982; 64:1376-1378.

6. Robinson SC, Driscoll SE. Simultaneous osteochondral avulsion of the femoral and tibial insertions of the anterior cruciate ligament. Report of a case in a 13-year-old boy. *J Bone Joint Surg Am*. 1981; 63:1342-1343.

7. Wasilewski SA, Frankl U. Osteochondral avulsion fracture of femoral insertion of anterior cruciate ligament. Case report and review of literature. *Am J Sports Med*. 1992; 20:224-226.

8. Donaldson WF III, Warren RF, Wickiewicz T. A comparison of acute anterior cruciate ligament examinations. Initial versus examination under anesthesia. *Am J Sports Med*. 1985; 13:5-10.

9. Bach BR Jr, Warren RF. "Empty wall" and "vertical strut" signs of ACL insufficiency. *Arthroscopy*. 1989; 5:137-140.

Section Editor: Steven F. Harwin, MD