

Surgical Technique: Medial Collateral Ligament Reconstruction Using Achilles Allograft for Combined Knee Ligament Injury

Robert G. Marx MD, MSc, FRCSC, Iftach Hetsroni MD

© The Association of Bone and Joint Surgeons® 2011

Abstract

Background Previous approaches for medial collateral ligament (MCL) reconstruction have been associated with extensive exposure, risk of donor site morbidity with autografts, loss of motion, nonanatomic graft placement, and technical complexity with double-bundle constructs. Therefore, we implemented a technique that uses Achilles allograft, small incisions, and anatomic insertions to reconstruct the MCL.

Description of Technique The MCL femoral insertion was identified, and a socket reamed over a guide pin. The Achilles bone plug was fixed in the socket and the tendon passed distally under the skin and fixed on the tibia, creating isometric reconstruction.

Each author certifies that he or she has no commercial associations (eg, consultancies, stock ownership, equity interest, patent/licensing arrangements, etc) that might pose a conflict of interest in connection with the submitted article.

Each author certifies that his or her institution approved the human protocol for this investigation, that all investigations were conducted in conformity with ethical principles of research, and that informed consent for participation in the study was obtained.

This work was performed at the Hospital for Special Surgery, Weill Medical College of Cornell University, New York, NY, USA.

R. G. Marx (✉)

Hospital for Special Surgery, Weill Medical College of Cornell University, 535 East 70th Street, New York, NY 10021, USA
e-mail: MarxR@hss.edu

I. Hetsroni

Department of Orthopedic Surgery, Meir General Hospital, Sapir Medical Center, Kfar Saba 44281, Israel

I. Hetsroni

Sackler Faculty of Medicine, Tel Aviv University, Tel Aviv, Israel

Patients and Methods We evaluated 14 patients who had this MCL reconstruction. We determined range of knee motion, knee ligament laxity, functional outcome scores (International Knee Documentation Committee [IKDC]-subjective, Lysholm, Knee injury and Osteoarthritis Outcome Score [KOOS]), and activity level scores (Tegner, Marx). Followup range was 24 to 61 months.

Results Knee motion was maintained in 12 cases. Grade 0-1 + valgus stability was obtained in all 14 cases. In cases of MCL with primary ACL reconstruction, IKDC-subjective, Lysholm, and KOOS-sports scores were 91 ± 6 , 92 ± 6 , and 93 ± 12 , respectively, and return to preinjury activity levels was achieved. In cases of MCL with revision ACL reconstruction, function was inferior, and patients did not return to their preinjury activity levels.

Conclusions This technique uses allograft that provides bone-to-bone healing on the femur, requires small incisions, and creates isometric reconstruction. When performed with a cruciate reconstruction, knee stability can be restored at 2 to 5 years followup. In patients with MCL with primary ACL reconstruction, return to preinjury activity level in recreational athletes can be achieved.

Introduction

The medial collateral ligament (MCL) is the primary restraint to valgus stability of the knee. At 30° flexion, it provides approximately 80% of the restraining force, whereas at full extension, it provides approximately 60% of the restraining force with the posteromedial capsule, posterior oblique ligament, and ACL providing the remaining restraint [12]. The superficial part of the MCL originates on an average of 3.2 mm proximal and 4.8 mm posterior to the medial epicondyle and inserts on the proximal tibia,

just anterior to the posteromedial crest of the tibia and posterior to the pes anserinus insertion [10, 18]. The deep part of the MCL originates inferior to the medial epicondyle and inserts on the tibia 1 cm below the joint line.

Nonoperative treatment of isolated MCL injuries reportedly results in similar stability as that afforded by surgical repair with less than 5-mm difference compared with the uninjured knee and return to athletic activity at a minimum 2-year followup in 90% of the cases [15]. However, when MCL injuries fail to heal, reconstruction may be advised to correct chronic instability or to prevent valgus overload on a reconstructed cruciate ligament [19, 26].

Several techniques have been described to reconstruct the MCL including semitendinosus autograft with preservation of the tibial insertion [2, 5, 17, 20], allograft tissues [4, 9], and double-bundle reconstructions [4, 9, 11, 17, 30]. However, some of these investigators who used a long incision across the medial aspect of the knee reported up to 20° loss of knee flexion or extension in 20% of their operations [20]. In addition, keeping the semitendinosus insertion distally and using it as an MCL graft [2, 5, 17, 20] results in a too-anterior tibial attachment (ie, the tibial insertion of the MCL should be posterior to the pes anserinus [10, 18]), and double-bundle reconstructions, compared with single-bundle reconstructions, are relatively complex, corresponding to their need for multiple attachment sites on the femur as well as on the tibia, more graft tissue, and number of fixation devices (ie, screws, washers, staples, etc) required [4, 9, 11, 17, 30].

Therefore, during the past 5 years, one of us (RGM) has been performing MCL reconstruction with a technique that uses Achilles tendon allograft. Benefits include avoiding donor site morbidity, secure fixation with bone-to-bone healing on the femur, small skin incisions that do not cross the knee, and isometric reconstruction. In addition, it is our impression this technique can be easily learned and implemented, which is particularly important for an uncommon procedure such as MCL reconstruction.

We describe this technique and evaluated knee motion, valgus stability, and function in 18 patients after the procedure.

Surgical Technique

The indications for this procedure were (1) a subjective sense of instability; (2) increased valgus laxity after 10 weeks of nonoperative treatment with a brace, graded as between 2+ and 3+ or above in the injured knee compared with the uninjured knee (ie, a difference of between 6 and 10 mm for Grade 2+ and above 10 mm for Grade 3+) [8, 14, 30]; (3) concomitant ACL instability (ie, Lachman

Grade 2B or above and a Grade 2+ pivot shift test) or posterior cruciate ligament (PCL) instability (ie, posterior drawer test Grade 2B or above at 90° flexion); and (4) arthroscopic finding confirming under valgus stress a medial compartment opening of more than 10 mm in the injured knee (this is measured with the tip of the arthroscopic probe used as a scale after its length is confirmed outside the knee). Open physis of the distal femur is an absolute contraindication for this surgery. Relative contraindications for this surgery include any factor that may substantially increase the risk of postoperative complications. These include (1) active infection; (2) inability to adhere to postoperative rehabilitation guidelines; (3) severe soft tissue trauma; and (4) comorbidities such as diabetes and morbid obesity.

With the patient under anesthesia, after confirming MCL laxity that requires reconstruction as indicated previously by physical examination and arthroscopic examination, the following steps were carried out (after fixing the cruciate graft on the femur): (1) The Achilles allograft was prepared creating a 9-mm diameter by 18-mm length bone plug (Fig. 1). (2) A 3-cm longitudinal skin incision was made over the medial femoral epicondyle. (3) We inserted a guide pin 3 to 5 mm proximal and posterior to the medial femoral epicondyle, parallel to the joint line, and in a 15° anterior direction to avoid the intercondylar notch. The location of the pin was confirmed with fluoroscopy (Fig. 2). (4) We undermined the skin from the femoral guide pin to the anatomic MCL insertion on the tibia, creating a tunnel for the graft under the subcutaneous fat (Fig. 3). (5) A nonabsorbable suture loop was placed around the guide pin and brought distally under the skin through the tunnel just created. (6) We held the distal suture against the tibia at the estimated anatomic insertion, just posterior to the pes anserinus insertion. Isometricity

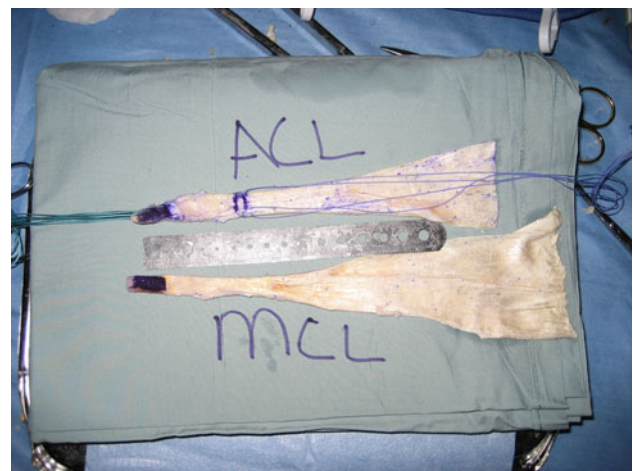


Fig. 1 The Achilles allograft is prepared on a side table. MCL = medial collateral ligament.

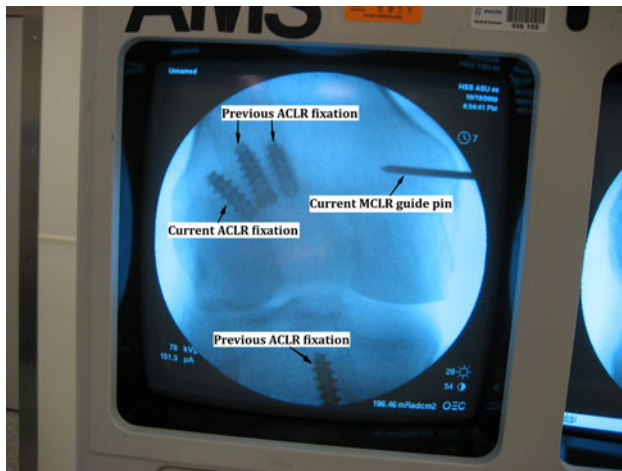

Fig. 2 Location of the pin is confirmed with fluoroscopy. ACLR = ACL reconstruction; MCLR = medial collateral ligament reconstruction.

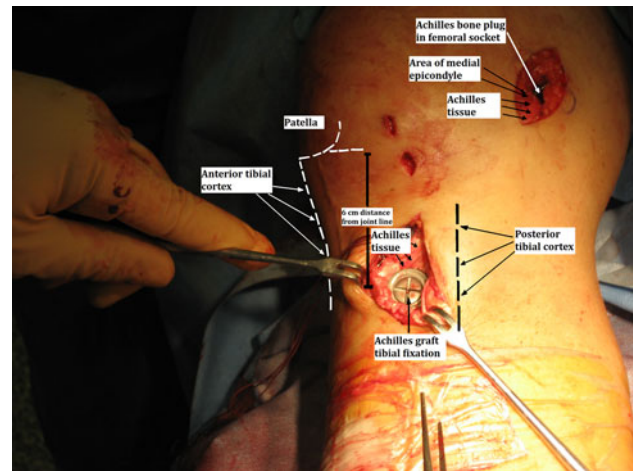


Fig. 4 The medial collateral ligament graft is fixed at the isometric point on the tibia.

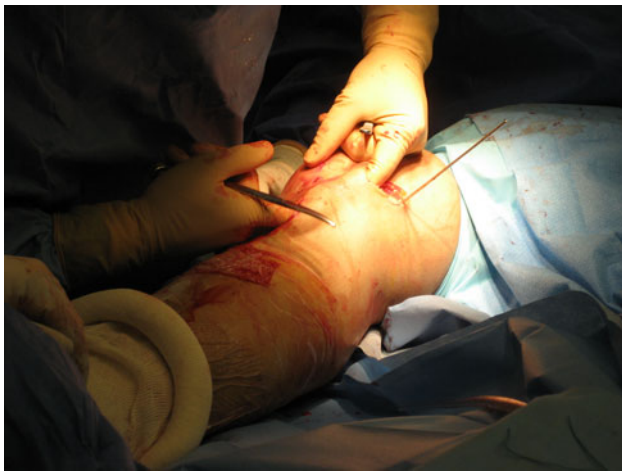

Fig. 3 Skin is undermined to create a tunnel for the graft across the knee.

was tested through knee motion from 0° to 90° . The tibial insertion point was modified, if needed, until the loop was isometric. (7) We marked the isometric point on the tibia with a Bovey. (8) Soft tissue around the guide pin was débrided to allow for insertion of the Achilles bone plug into a socket created around this pin later. (9) We reamed over the guide pin with a 9-mm diameter reamer to a depth of 20 mm. (10) We inserted the Achilles bone plug into the femoral socket and fixed with a 7-mm diameter by 20-mm length metal interference screw. (11) The Achilles tendon tissue was passed under the skin and distally. (12) We then tensioned the cruciate graft and fixed it on the tibia. (13) The MCL graft was tensioned with the knee at 20° flexion under varus stress and fixed at the isometric point on the tibia with a 4.5-mm cortical screw and a 17-mm spiked washer (Fig. 4). (14) The subcutaneous tissue and

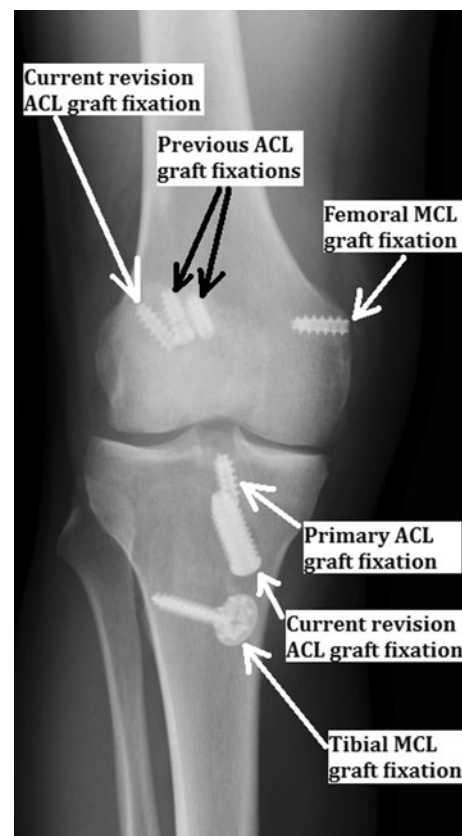


Fig. 5 Postoperative knee in AP view. MCL = medial collateral ligament.

skin were closed. We confirmed tunnel position and hardware placement with postoperative radiographs (Fig. 5).

If the ACL was reconstructed but not the PCL, then we recommended the following postoperative guidelines: (1) toe touch was allowed with a knee brace locked in extension for 2 weeks; (2) at 2 weeks postoperatively, knee

motion in the brace was allowed from 0° to 60°; (3) at 4 weeks postoperatively, knee motion was expected to reach 60° flexion. Full weightbearing was allowed and knee flexion encouraged beyond 60° to reach 90°; (4) at 6 weeks, the brace was removed and progression to full ROM allowed; (5) progressive ROM and strength training were emphasized; and (6) crutches were used until gait was normal. If the PCL was also reconstructed, the postoperative care followed postoperative guidelines for PCL reconstruction [6]. These included (1) a long leg brace locked in extension and nonweightbearing for postoperative Weeks 1 through 5; (2) the brace was then unlocked, progressive ROM performed, and weightbearing advanced at 20% body weight per week; (3) at the end of postoperative Week 10, the brace was discontinued and unassisted weightbearing encouraged; and (4) progressive ROM and strength training was instituted.

Patients and Methods

We retrospectively reviewed the records of all 18 patients who had concomitant MCL and either ACL or PCL reconstructions from August 2005 to September 2008. Inclusion criterion was minimum 2 years followup. We excluded two patients: one for an isolated MCL reconstruction using the approach and one who had a concomitant high tibial osteotomy. This left 16 patients for study; however, one was lost to followup and another unwilling to return for a recall visit. After these two further exclusions, 14 were available for a minimum 2-year followup. In these 14 patients, the MCL was reconstructed using the previously mentioned technique in four different scenarios (Table 1). These included primary ACL reconstruction, revision ACL reconstruction, primary PCL reconstruction, and ACL/PCL/lateral collateral ligament (LCL)/PLC knee reconstruction. Average age at surgery was 34 years (range, 19–60 years). Average time from injury to surgery was 5.7 months (range, 2–12 months) in cases with concomitant primary ACL reconstruction. Minimum time from surgery to latest followup was 24 months (average, 36 months; range, 24–61 months). All

14 patients were recalled specifically for this study. This study was approved by our Institutional Review Board and all subjects signed informed consent.

All latest followup examinations for this study were performed by a single orthopaedic surgeon (IH) who was not involved in the treatment of these patients. At the last visit we recorded the following: age at the time of surgery, followup duration, range of knee motion, side-to-side ligament laxity difference assessed by physical examination, functional outcome scores, and activity level scores. ACL laxity was assessed with the Lachman, anterior drawer (graded as 0 for 0–2 mm side-to-side difference, 1+ for 3–5 mm difference, 2+ for 6–10 mm difference, 3+ for more than 10 mm difference) [16], and pivot shift test (graded as 0 for no pivot, 1+ for “glide,” 2+ for clear clunk). PCL laxity was assessed with the posterior drawer test at 90° knee flexion (graded as 0 for 0–2 mm side-to-side difference, 1+ for 3–5 mm difference and with anterior medial tibial plateau located anterior to the medial femoral condyle, 2+ for 6–10 mm difference and with anterior medial tibial plateau located flush with the medial femoral condyle, 3+ for more than 10 mm difference and with anterior medial tibial plateau located posterior to the medial femoral condyle) [29]. MCL laxity was assessed with valgus stress test at 0° and at 30° knee flexion (graded as 0 for 0–2 mm side-to-side difference, 1+ for 3–5 mm difference, 2+ for 6–10 mm difference, 3+ for more than 10 mm difference) [8, 14, 30] in addition to the antero-medial rotatory instability test [13]. LCL/PCL laxity was assessed with a varus stress test at 0° and at 30° knee flexion (graded as 0 for 0–2 mm side-to-side difference, 1+ for 3–5 mm difference, 2+ for 6–10 mm difference, 3+ for more than 10 mm difference), external rotation with a posterior drawer test at 90° knee flexion (graded as 0, 1+, 2+, 3+), and a dial test at 30° knee flexion (considered positive with side-to-side difference greater than 15°) [7, 29]. Functional outcome scores included the International Knee Documentation Committee (IKDC) subjective knee score [1], Lysholm knee score [21], and Knee injury and Osteoarthritis Outcome Score (KOOS) score [27]. Activity level was assessed with Tegner score [28] and Marx score [22].

Table 1. Type of concomitant reconstruction, meniscus surgery, and patient demographics

Type of concomitant reconstruction	Number of patients	Number of resected meniscus knees	Number of repaired meniscus knees	Mean age at surgery (range)	Gender (male/female)
Primary ACLR	7	4	2	34 (25–48)	3/4
Revision ACLR	5	3	2	24 (19–34)	3/2
Primary PCLR	1	1	0	60	0/1
Primary ACLR/PCLR/PLCR	1	0	0	59	0/1

ACLR = anterior cruciate ligament reconstruction; PCLR = posterior cruciate ligament reconstruction; PLCR = posterolateral and lateral side reconstruction.

Descriptive statistics consisted of means, ranges, and standard deviations.

Results

At last followup, no patient had gross malalignment or gait abnormalities (ie, limp, varus thrust, or valgus thrust).

In 12 of the 14 patients, range of knee motion was maintained and symmetric compared with the uninjured knee. In the group of patients that had MCL reconstruction with primary ACL reconstruction, none had loss of knee motion. In the group that had MCL reconstruction with revision ACL reconstruction, one patient had 15° knee flexion loss. One patient who had MCL reconstruction with ACL/PCL/LCL/PLC reconstruction had 15° knee flexion loss as well.

Side-to-side ligament integrity examination revealed that all reconstructed MCL grafts had a firm end point on valgus stress test with no or minimal side-to-side differences (ie, no side-to-side difference in 11 patients and Grade 1+ in three patients). One patient who had MCL reconstruction with primary ACL reconstruction and one patient who had MCL reconstruction with revision ACL reconstruction had pivot shift Grade 2+. Both reported possible feeling unstable during cutting but not in everyday activities. All other ligament laxity tests were symmetric and normal.

IKDC-subjective, Lysholm, and KOOS-sports scores (Table 2) were 91 ± 6 , 92 ± 6 , and 93 ± 12 , respectively, in cases of MCL reconstruction with primary ACL

reconstruction. These patients also demonstrated return to preinjury activity levels. In cases of MCL reconstruction with revision ACL reconstruction, despite restoration of Grade 0–1+ valgus stability with the MCL graft, functional scores were inferior, and patients did not return to their preinjury activity levels.

Discussion

Previous approaches for MCL reconstruction were associated with several limitations. These included donor site morbidity and nonanatomic insertion site of the MCL graft on the tibia (ie, too anterior) when preserving the insertion of a semitendinosus autograft [2, 5, 17, 20], need for long incisions across the medial side of the knee, and relative technical complexity when using double-bundle constructs [4, 9, 11, 17, 30]. Harvesting a dynamic medial stabilizer that applies adduction moment during gait (ie, semitendinosus) in a knee with an already medial instability may pose another limitation in our opinion. Therefore, a new technique that avoids the risks of donor site morbidity and the complexity of double-bundle constructs and uses Achilles tendon allograft that provides bone-to-bone healing on the femur with anatomic insertion sites and small skin incisions has been developed. The purpose of this study was to describe this technique and to report subsequent knee motion, stability, and function in a series of patients that had MCL reconstruction using this technique in the setting of combined MCL with cruciate ligament instability.

Table 2. Functional and activity level scores in each scenario of MCLR (mean \pm SD)

Score	Primary ACLR (n = 7)	Revision ACLR (n = 5)	Primary PCLR (n = 1)	Primary ACLR/PCLR/PLCR (n = 1)
IKDC subjective	91 ± 6	73 ± 15	76	81
Lysholm	92 ± 6	77 ± 10	89	93
KOOS				
Pain	96 ± 4	83 ± 13	92	100
ADL	99 ± 1	93 ± 11	94	97
Sports	93 ± 12	67 ± 22	55	87
Knee symptoms	89 ± 12	79 ± 12	93	96
Quality of life	77 ± 17	54 ± 17	50	94
Marx				
Before injury	7 ± 7	13 ± 5	0	2
After reconstruction	6 ± 5	5 ± 4	0	2
Tegner				
Before injury	6 ± 2	7 ± 3	3	1
After reconstruction	6 ± 2	5 ± 2	3	1

ACLR = anterior cruciate ligament reconstruction; PCLR = posterior cruciate ligament reconstruction; PLCR = posterolateral and lateral side reconstruction; IKDC = International Knee Documentation Committee; KOOS = Knee injury and Osteoarthritis Outcome Score; ADL = activities of daily living.

Table 3. Reports on outcome after MCL reconstruction using a specific technique

Study	Graft used	Number of patients*	Followup (years)	ROM limit (%) [†]	Medial stability 0–1+ (%)	Lysholm score (range)	KOOS subscores (range)
Kim et al. [17]	Semitendinosus autograft	24	2–7.5	21	> 90	80–100	NR
Lind et al. [20]	Semitendinosus autograft	50	> 2	20	> 90	NR	75–89
Marx et al. (current study)	Achilles allograft	14	2–5	14	100	85–100 [‡]	77–96 [‡]

* In Kim et al., there were only 18 cases of combined MCL and another cruciate ligament reconstruction; in Lind et al., there were only 39 cases of combined MCL and another cruciate ligament reconstruction; [†]percentage of patients in the study group that had motion limit greater than 5°; [‡]in the MCL and primary cruciate reconstructions; MCL = medial collateral ligament; KOOS = Knee injury and Osteoarthritis Outcome Score; NR = not reported.

We note limitations to our study. First, we had a relatively small number of patients owing to the uncommonness of indications for this type of surgery. Nevertheless, because all operations were performed by a single surgeon, low technical variability of the MCL reconstruction is expected in our series, and this may be of particular importance when evaluating stability and function after the operation in such small numbers. Second, our outcome evaluation in terms of knee stability relied on physical examination according to an accepted grading system [8, 14, 30], but we did not use objective measures such as KT-1000 or stress radiographs. Third, because functional scores (ie, IKDC-subjective and Lysholm) were collected systematically only postoperatively but not preoperatively, postoperative improvement in function could not be quantified. Lastly, we had a heterogeneous group of concomitant ligament reconstructions, which could make it difficult to relate our results to a specific knee reconstruction scenario. To address this, we categorized our patients into four groups and reported outcomes separately in each of the four ligament reconstruction scenarios we had (ie, MCL with primary ACL, MCL with revision ACL, MCL with primary PCL, MCL in a four-ligament knee reconstruction).

Twelve of our 14 cases regained full motion. This shows the new technique is unlikely to cause motion loss, probably as a result of the fact it is extra-articular, yet in one case of MCL with concomitant revision ACL reconstruction and in a case that involved ACL/PCL/LCL/PLC knee reconstruction, 15° flexion loss was observed. This observation supports the use of the technique described viewing that motion loss is expected after complex knee reconstructions that include MCL reconstruction and at least another cruciate reconstruction [8, 17, 20]. We found two studies reporting ROM and function in patients who had MCL reconstruction with one similar graft tissue in all patients and a similar specifically described a reconstruction technique for the MCL in a combined MCL and another cruciate reconstruction [17, 20] (Table 3). Both

described a technique that uses the semitendinosus tendon with preservation of the insertion site at the pes anserinus on the tibia, creating anterior and posterior limbs to reconstruct the MCL. However, in both studies, the group of patients was heterogeneous and included isolated MCL reconstructions as well as concomitant cruciate reconstructions, but ROM was reported for all patients as one group, not differentiating the combined reconstructions from the isolated MCL reconstructions. In one of these, which included six cases of isolated MCL reconstruction and 18 cases of MCL with another cruciate reconstruction, the investigators found motion limitation between 5° and 10° in extension or in flexion in five patients (21% of the patients) [17], whereas in the other study, which included 11 cases of isolated MCL reconstruction and 39 cases of MCL with another one or both cruciate ligament reconstructions or posterolateral corner reconstruction, the investigators noticed motion loss of between 5° and 20° in extension or in flexion in 10 patients (20% of the patients) [20]. Both studies did not report ROM specifically for the combined reconstructions, and therefore the comparison to our results is limited because we evaluated only combined ligament reconstructions.

All MCL grafts in our patients demonstrated Grade 0–1+ valgus laxity on physical examination. Bone-to-bone healing on the femur, strong and broad Achilles tendon allograft tissue, isometric reconstruction, and secure fixation on both insertion sites may all account for this. This is comparable to previous reports after double-bundle MCL reconstruction in a combined ligament reconstruction scenario that described Grade 0 to 1+ valgus laxity in more than 90% of their cases (Table 3) [17, 20].

Mean IKDC-subjective and Lysholm knee scores demonstrated excellent (ie, above 90 points) [23–25] function in patients with MCL reconstruction and primary ACL reconstruction. This is comparable to the mean Lysholm score reported by others when creating a double-bundle MCL reconstruction with the semitendinosus, preserving its tibial insertion (Table 3) [17]. Mean KOOS subscores in

our series were between 77 and 96 for the five categories of the score in cases with primary ACL reconstruction, which is comparable to another study that created a double-bundle MCL reconstruction and reported mean KOOS subscores between 75 and 89 for MCL reconstruction in a multiligament reconstruction scenario, the vast majority of which were MCL with ACL reconstructions [20]. In patients with MCL reconstruction with revision ACL reconstruction in our series, IKDC-subjective, Lysholm, and KOOS subscores demonstrated inferior outcome. Because revision ACL reconstructions reportedly are associated with inferior function compared with primary ACL reconstructions for multiple reasons [3, 31], this result is expected. Tegner and Marx activity level scores demonstrated patients with concomitant primary ACL reconstruction were able to return to preinjury activity levels, which were at means of between 6 and 7 points, indicating that cutting and pivoting sports on a recreational level may be a realistic goal after this type of MCL reconstruction.

This technique uses allograft that provides bone-to-bone healing on the femur, requires small incisions, and creates isometric reconstruction. When performed with a cruciate reconstruction, knee stability can be restored at 2 to 5 years followup. In cases of MCL with primary ACL reconstruction, return to preinjury activity level in recreational athletes can be achieved. In cases of extreme laxity, in which valgus stability is not restored after this procedure, we recommend considering adding posteromedial capsular reefing, and each case should be evaluated individually.

References

- Anderson AF, Irrgang JJ, Kocher MS, Mann BJ, Harrast JJ. The International Knee Documentation Committee subjective knee evaluation form: normative data. *Am J Sports Med.* 2006;34:128–135.
- Azar FM. Evaluation and treatment of chronic medial collateral ligament injuries of the knee. *Sports Med Arthrosc Rev.* 2006;14:84–90.
- Battaglia MJ 2nd, Cordasco FA, Hannafin JA, Rodeo SA, O'Brien SJ, Altchek DW, Cavanaugh J, Wickiewicz TL, Warren RF. Results of revision anterior cruciate ligament surgery. *Am J Sports Med.* 2007;35:2057–2066.
- Borden PS, Kantaras AT, Caborn DNM. Medial collateral ligament reconstruction with allograft using a double-bundle technique. *Arthroscopy.* 2002;18:E19.
- Bosworth DM. Transplantation of the semitendinosus for repair of laceration of medial collateral ligament of the knee. *J Bone Joint Surg Am.* 1952;34:196–202.
- Fanelli GC, Boyd JL, Heckler MW. How I manage posterior cruciate ligament injuries. *Oper Tech Sports Med.* 2009;17:175–193.
- Fanelli GC, Edson CJ. Combined posterior cruciate ligament–posterolateral reconstructions with Achilles tendon allograft and biceps femoris tenodesis: 2- to 10-year follow-up. *Arthroscopy.* 2004;20:339–345.
- Fanelli GC, Harris JD. Late medial collateral ligament reconstruction. *Tech Knee Surg.* 2007;6:99–105.
- Fanelli GC, Tomaszewski DJ. Allograft use in the treatment of the multiple ligament injured knee. *Sports Med Arthrosc Rev.* 2007;15:139–148.
- Feeley BT, Muller MS, Allen AA, Granchi CC, Pearle AD. Isometry of medial collateral ligament reconstruction. *Knee Surg Sports Traumatol Arthrosc.* 2009;17:1078–1082.
- Feeley BT, Muller MS, Allen AA, Granchi CC, Pearle AD. Biomechanical comparison of medial collateral ligament reconstructions using computer-assisted navigation. *Am J Sports Med.* 2009;37:1123–1130.
- Grood ES, Noyes FR, Butler DL, Suntay WJ. Ligamentous and capsular restraints preventing straight medial and lateral laxity in intact human cadaver knees. *J Bone Joint Surg Am.* 1981;63:1257–1269.
- Hughston JC, Barrett GR. Acute anteromedial rotatory instability. Long-term results of surgical repair. *J Bone Joint Surg Am.* 1983;65:145–153.
- Hughston JC, Eilers AF. The role of the posterior oblique ligament in repairs of acute medial (collateral) ligament tears of the knee. *J Bone Joint Surg Am.* 1973;55:923–940.
- Indelicato PA. Non-operative treatment of complete tears of the medial collateral ligament of the knee. *J Bone Joint Surg Am.* 1983;65:323–329.
- Jonsson T, Althoff B, Peterson L, Renstrom P. Clinical diagnosis of ruptures of the anterior cruciate ligament: a comparative study of the Lachman test and the anterior drawer sign. *Am J Sports Med.* 1982;10:100–102.
- Kim SJ, Lee DH, Kim TE, Choi NH. Concomitant reconstruction of the medial collateral and posterior oblique ligaments for medial instability of the knee. *J Bone Joint Surg Br.* 2008;90:1323–1327.
- La Prade RF, Engebretsen AH, Ly TV, Johansen S, Wentorf FA, Engebretsen L. The anatomy of the medial part of the knee. *J Bone Joint Surg Am.* 2007;89:2000–2010.
- Larson RL. Combined instabilities of the knee. *Clin Orthop Relat Res.* 1980;147:68–75.
- Lind M, Jakobsen BW, Lund B, Hansen MS, Abdallah O, Christiansen SE. Anatomical reconstruction of the medial collateral ligament and posteromedial corner of the knee in patients with chronic medial collateral ligament instability. *Am J Sports Med.* 2009;37:1116–1122.
- Lysholm J, Gillquist J. Evaluation of knee ligament surgery results with special emphasis on use of a scoring scale. *Am J Sports Med.* 1982;10:150–154.
- Marx RG, Stump TJ, Jones EC, Wickiewicz TL, Warren RF. Development and evaluation of an activity rating scale for disorders of the knee. *Am J Sports Med.* 2001;29:213–218.
- Mitsou A, Vallianatos P, Piskopakis N, Maheras S. Anterior cruciate ligament reconstruction by over-the-top repair combined with popliteus tendon plasty. *J Bone Joint Surg Br.* 1990;72:398–404.
- Moller E, Weidenhielm L, Werner S. Outcome and knee-related quality of life after anterior cruciate ligament reconstruction: a long term follow-up. *Knee Surg Sports Traumatol Arthrosc.* 2009;17:786–794.
- Odensten M, Lysholm J, Gillquist J. Long-term follow-up study of a distal iliotibial band transfer (DIT) for anterolateral knee instability. *Clin Orthop Relat Res.* 1983;176:129–135.
- Robins AJ, Newman AP, Burks RT. Postoperative return of motion in anterior cruciate ligament and medial collateral ligament injuries: the effect of medial collateral ligament rupture locations. *Am J Sports Med.* 1993;21:20–25.
- Roos EM, Roos HP, Lohmander LS, Ekdahl C, Beynon BD. Knee injury and Osteoarthritis Outcome Score (KOOS)—development

- of a self-administered outcome measure. *J Orthop Sports Phys Ther.* 1998;28:88–96.
28. Tegner Y, Lysholm J. Rating systems in the evaluation of knee ligament injuries. *Clin Orthop Relat Res.* 1985;198:43–49.
 29. Veltri DM, Warren RF. Isolated and combined posterior cruciate ligament injuries. *J Am Acad Orthop Surg.* 1993;1:67–75.
 30. Wijdicks CA, Griffith CJ, Johansen S, Engebretsen L, La Prade RF. Injuries to the medial collateral ligament and associated medial structures of the knee. *J Bone Joint Surg Am.* 2010;92:1266–1280.
 31. Wright RW, Dunn WR, Amendola A, Andrish JT, Flanigan DC, Jones M, Kaeding CC, Marx RG, Matava MJ, McCarty EC, Parker RD, Vidal A, Wolcott M, Wolf BR, Spindler KP; MOON Cohort. Anterior cruciate ligament revision reconstruction: two-year results from the MOON Cohort. *J Knee Surg.* 2007;20:308–311.