



Sideline Orthopedic Emergencies in the Young Athlete

Robert G. Marx, MD, MSc, FRCSC; and J. Scott Delaney, MD, FRCPC

Many orthopedic emergencies can occur during a sporting event when children and adolescents are involved. This article covers the basic principles involved in three common orthopedic problems that are seen in sports medicine. Cervical spine injuries are potentially devastating and all physicians involved in children's athletic coverage should be comfortable with the initial evaluation and transport of suspected cervical spine trauma. Shoulder dislocations are common in adolescents. An understanding of the pathology and natural history of this injury is important for physicians who are on the sidelines of sporting events, especially contact sports such as football and hockey. Finally, knowledge of basic principles regarding the acute management of fractures, including open fractures, is important for pediatricians because fractures are common events in many types of sports and also frequently present to the pediatric office.

CERVICAL SPINE INJURIES

A 16-year-old high school football player tackled an opposing player, leading with his head. He suffered an obvious axial load injury to his neck and collapsed motionless on the field. He describes a momentary lack of consciousness, complains of severe neck pain, and states that he is unable to feel or move his arms or legs.

Dr. Marx is Orthopedic Director, Sports Medicine Institute for Young Athletes, Hospital for Special Surgery, and Assistant Professor, Orthopedic Surgery & Public Health, Weill Medical College of Cornell University, New York, New York. Dr. Delaney is Assistant Professor and Attending Staff, Department of Emergency Medicine, McGill University Health Center, and Attending Staff, McGill Sport Medicine Clinic, Montreal, Quebec, Canada. Address reprint requests to Robert G. Marx, MD, MSc, FRCSC, Orthopedic Surgery and Sports Medicine, Hospital for Special Surgery, 535 East 70th Street, New York, NY 10021.

EDUCATIONAL OBJECTIVES

1. Review the initial evaluation and transport of suspected cervical spine trauma in the young athlete.
2. Discuss the pathology and natural history of shoulder dislocations.
3. Review the basic principles of acute fracture management, including open fractures.

Pediatric cervical spine injuries are rare, occurring in fewer than 2% of pediatric patients with blunt trauma.^{1,2} Although infrequent, these injuries can result in death or permanent paralysis and long-term disability. Therefore, pediatricians who may be called on to assess and treat injured young athletes should possess a good understanding of the anatomy and the biomechanics of the pediatric cervical spine, the types of injuries that may be seen, and which patients should be immobilized on the field of play.

Cervical injuries comprise approximately 60% to 80% of all pediatric spinal injuries.³ In comparison, they account for only 30% to 40% of all adult spinal injuries.^{2,3} Children in the second decade of life sustain most of their cervical spine injuries while participating in sports and recreational activities.⁴ Young children are injured less frequently during sporting activities. Falls and pedestrian accidents account for most cervical spine injuries in this age group.³

Certain sports and recreational activities are believed to have a higher risk for cervical spine injuries than others (Table 1). Although it may be intuitive that football and ice hockey place children at higher risk for cervical spine injuries than

does a sport such as tennis, children diving into a pool and striking their heads on the bottom (aquatics) and those falling from trampolines account for a large number of serious cervical spine injuries and deaths.⁶

Anatomy

The pediatric cervical spine is much more flexible than the adult cervical spine. There are several reasons for this. A child's interspinous ligaments, cartilaginous end plates, and spinal joint capsules have greater elasticity and laxity.^{3,7} The facet joints are shallow and more horizontally oriented throughout the spine, especially in the cervical area.⁸ These shallow angles allow more forward translational movement of the vertebral bodies. The vertebral bodies in the upper cervical spine of a young child are wedge-shaped anteriorly, which also allows easier forward translational movement.^{3,9} All of these factors mean that a significant amount of movement of the cervical spine can occur without fractures or ligamentous injury to the vertebral column. Due to the proportionately larger heads and weaker neck muscles of children younger than 8 years, the fulcrum of movement in the cervical spine is at the level of C2 to C3. This probably explains why most cervical spine injuries in children younger than 8 years occur in the upper cervical area (C1-C4).^{3,10,11}

As a child grows, the anatomy and the biomechanics of the cervical spine begin to transition to those of an adult. It is generally accepted that after the age of 8 years, the cervical spine is similar to that of an adult. The ligaments, end plates, and joint capsules become less elastic, the facet joints become more vertically oriented, and the vertebral bodies of the cervical spine become less wedge-shaped. As the neck muscles become stronger and the head takes on more adult proportions, the fulcrum of cervical movement migrates lower in the cervical spine, until it is at the adult level of C5 to C6 by approximately 8 years of age. This explains why children older than 8 years are more likely to experience cervical spine injuries in the lower cervical levels (C5-C8).^{3,4,10}

Types of Injuries

The anterior spinal column consists of the vertebral bodies and supporting ligaments. The pos-

| TABLE 1 Sports and Recreational Activities With a Higher Risk for Cervical Spine Injury* | |
|--|--|
| Football | |
| Ice hockey | |
| Gymnastics | |
| Cheerleading | |
| Aquatics | |
| Equestrian | |
| Rugby | |
| Wrestling | |
| Lacrosse | |
| Trampoline | |
| Tobogganing | |
| <small>*Data from Clarke.⁵</small> | |

terior elements consist of the pedicles, the laminae, the facets, and the supporting ligaments. Although pediatric cervical spine injuries may involve fractures, subluxations, dislocations (Fig. 1), and combinations thereof, the pediatric cervical spinal cord is also at risk for injury without any damage to the anterior or the posterior elements.^{1,10,12} These injuries have been termed spinal cord injuries without radiographic abnormalities (Fig. 2).^{1,9,13} They occur when the transient deformation of the vertebral column injures the spinal cord and the vertebral column then returns to its normal alignment without significant damage. Spinal cord injuries without radiographic abnormalities have been estimated to occur in anywhere between 5% and 67% of all pediatric spinal cord injuries.⁹

The pediatric vertebral column is more elastic than the spinal cord it surrounds.⁸ In fact, a young vertebral column can be distracted or stretched more than 5 cm (2 in) before it will rupture, whereas a spinal cord will rupture after 5 to 6 mm (1/4 in) of stretch.^{3,13,14} Spinal cord injury without radiographic abnormalities most commonly affects children younger than 16 years and results from flexion, extension, or distraction forces. Similar to cervical spine injuries in general, spinal cord injury without radiographic abnormalities most commonly affects the upper cervical cord (C1-C4) in children younger than 8 years, whereas older children are more likely to



Figure 1. Cervical spine dislocation (bilateral facet jump). Note the malalignment of the vertebral bodies (white arrow).

have lower cervical lesions (C5–C8). Younger children are also more likely to have spinal cord injuries without radiographic abnormalities that result in complete or severe spinal cord lesions, whereas older children are more likely to experience mild spinal cord injuries.⁹

Assessment and Diagnosis on the Field

As a general rule, most injured athletes should be assumed to have a cervical spine injury until proven otherwise. This includes any injured athlete in whom a neck injury is suspected or anyone with an uncertain mechanism of injury. Because secondary movement of the vertebral column can




Figure 2. Lateral x-ray of the cervical spine showing normal alignment.

worsen or cause injury to the cervical spinal cord, it is always preferable to err on the side of caution and immobilize the cervical spine. In many situations, it is obvious that a cervical spine injury may have occurred (Table 2). However, any unconscious patient should be assumed to have a cervical spine injury, especially if the cause of injury was unwitnessed. Any patient who has an altered level of consciousness should be considered an unreliable source and cannot be trusted to answer questions regarding symptoms correctly. An athlete with a painful injury that may distract the medical team (eg, a fractured long bone) should not be expected to appreciate mild discomfort in the neck area from an injury. All of these situations should be treated as possible cervical spine injury.

In some situations, cervical spine injuries are unlikely. Unless a child has been involved in a

motor vehicle accident, studies have shown that it is unlikely for him or her to have sustained a cervical spine injury if he or she is awake, has a normal mental status for age, and has no complaints or signs of neck pain.^{16,17} Cervical spine injuries are also uncommon when children have fallen from heights of less than 5 to 10 feet.¹⁸ Even children younger than 10 months who have suffered cervical spine injuries will usually present with either torticollis or a refusal to move their necks.¹⁷ However, the physician should be cautious when dealing with an unfamiliar nonverbal child who may have fallen. Because of the difficulty in communicating with and reliably assessing the nonverbal child, the physician may wish to immobilize such patients.¹¹

Immobilization

All athletes, regardless of age, who may have suffered a cervical spine injury should have cervical spine immobilization (Table 2). Although many junior high and high school sports teams have a supervising therapist or trainer with a standardized protocol for assessing and immobilizing injured athletes, most children who participate in organized sports and almost all who play sports recreationally will not have such supervision. Thus, it is helpful for physicians or other health care professionals who may be called on to assess an injured child to be familiar with basic cervical spine immobilization techniques.

The assessment of the airway, breathing, and circulation (ABCs) always takes priority, but this can be accomplished while maintaining cervical spine immobilization. Once the decision has been made to immobilize an injured athlete, the local emergency medical services should be activated so that the athlete can be expediently transported to a hospital for more definitive assessment.

The Supine Athlete. When assessing the athlete with a potential cervical spine injury, the physician should kneel close to the athlete's head and speak to him or her in a calm fashion. Being close to the injured athlete removes the temptation for the athlete to turn his or her head around to speak. The athlete should be told to not move his or her neck.

If, after speaking to the athlete, the physician decides to immobilize the cervical spine, the physician should kneel at the athlete's head, look-

| TABLE 2 When to Suspect a Cervical Spine Injury in an Athlete* | |
|---|--|
| The athlete | |
| | Is unconscious |
| | Has an altered level of consciousness (includes concussions) |
| | Has neck pain |
| | Has midline bony tenderness on palpation |
| | Has neurologic signs or symptoms (especially in the extremities or upper chest area) |
| | Has an injury that may distract him or her, the medical team, or both (eg, long bone fracture) |
| | Is nonverbal with a suitable mechanism of injury (eg, fall from a height of more than 10 feet) |
| <small>*Data from Viccellio et al.¹² and Jaffe et al.¹⁵</small> | |

ing down toward the athlete's feet, and cradle the athlete's head. The athlete's cervical spine is therefore immobilized in a secure fashion. The athlete cannot move his or her head and the physician is in a secure position such that even if the physician is bumped, there will be no movement of the athlete's cervical spine on either side of the neck. If possible, the physician should perform a brief neurologic examination, including level of consciousness, pupillary size, and extremity strength and sensation. This initial information will be invaluable for determining whether there is any change in the patient's condition later.

The Prone Athlete. Assessing and immobilizing a prone athlete presents more of a challenge, because he or she may have to be turned to the supine position at some point. This is usually required if the athlete is unconscious or there is a question about airway integrity. When necessary, this is done by "log-rolling" the athlete while one person controls his or her head and neck, a second person controls his or her shoulders and thorax, and a third person controls his or her hips and legs.

The position of the hands of the person at the athlete's head can be confusing for those not familiar with prone log-rolling techniques. A good rule is to start by considering where the hands will be in the final position and work backwards. The immobilizer should kneel at the head of the athlete

as he or she would for the supine athlete and place his or her hands in the final supine position (ie, where the thumbs are on top pointing toward the athlete's nipples). The immobilizer should then rotate his or her hands in a reverse fashion to which the athlete is to be rolled. For example, if the athlete is prone and must be turned to the right to end up supine, the immobilizer should start with his or her hands on the right side in the final position and turn them back in toward the athlete until they are on either side of the athlete's head. The immobilizer can then grasp the area where the trapezius meets the neck on each side of the head and secure the head between his or her forearms. The other immobilizers at the shoulders and the hips should follow the directions of the immobilizer at the head and neck and all should roll in unison on the command "prepare to roll—roll."¹⁹

Board Immobilization. Emergency medical service personnel should be familiar with long spinal board immobilization techniques and should be expected to control further immobilization or movement of the injured athlete onto the spinal board.^{20,21} Athletes should have a hard cervical collar placed on them before being moved onto a spinal board. Once the athlete is placed on the board, foam or sandbag immobilizers are taped into place on either side of his or her head to further stabilize the cervical spine. Straps are fastened across the body to secure the athlete to the spinal board. Because children younger than 8 years have proportionately larger heads than older children and adults, the large occiput region can cause the cervical spine to bend into a flexed position when they are placed in a supine position on the flat board.²²⁻²⁵ Therefore, young children should have a double mattress pad placed under their back to elevate their chest and thorax when placed on a flat spinal board. Elevating the chest and thorax will allow the cervical spine to stay in a neutral position, with the head resting on the board. Alternatively, some spinal boards have an area cut out for the occiput, which again prevents flexion of the cervical spine when the young child is placed supine on a spinal board.

The athlete with a spinal injury and impaired sensation should be removed from the board as soon as possible. This is because he or she will be at risk for pressure sores, particularly if the board

is hard. The ideal surface for such a patient is firm but padded.

Equipment. Cervical spine injuries may occur in athletes who are wearing equipment such as mouth guards, helmets, and shoulder pads. All mouth guards and dental appliances should be removed from the injured athlete. For athletes who wear shoulder pads, the back and the chest should be elevated when supine. Helmets usually elevate the occiput in the supine position and thus prevent the head from falling back into hyperextension in this situation. Helmets should thus be left in place except under the rarest of conditions¹⁹ (Figs. 3 and 4). Although the helmet should stay on with the chin guard fastened, face masks should be removed from all immobilized athletes. This allows airway access and can usually be accomplished easily by removing the screws with a screwdriver, or by cutting away the clear plastic loop straps that often secure the face mask to the helmet with a sharp device.

SHOULDER DISLOCATIONS

A 14-year-old wrestler attempted to flip an opponent, but the move was blocked. He collapsed to the mat complaining of shoulder pain. There is an obvious deformity at the shoulder and the athlete states that he dislocated his shoulder once before and that the same thing has happened again.

Sports-related injuries of the shoulder are common. Dislocations of joints in the shoulder area most often involve either the glenohumeral joint or the acromioclavicular joint. Acute injuries to the acromioclavicular joint are commonly referred to as "shoulder separations." However, when physicians refer to "shoulder dislocations," they are almost always referring to dislocations of the glenohumeral joint. In this article, shoulder dislocations refer only to dislocations of the glenohumeral joint.

Shoulder dislocations are common. Epidemiologic studies have demonstrated that 0.5% to 1.7% of all individuals have a positive history for shoulder dislocation.^{26,27} Glenohumeral dislocations tend to recur, especially among children.^{26,28} In fact, adolescents who are involved in sports, particularly contact sports, typically have a rate of recurrence approaching 100%.²⁸⁻³⁵ In general,

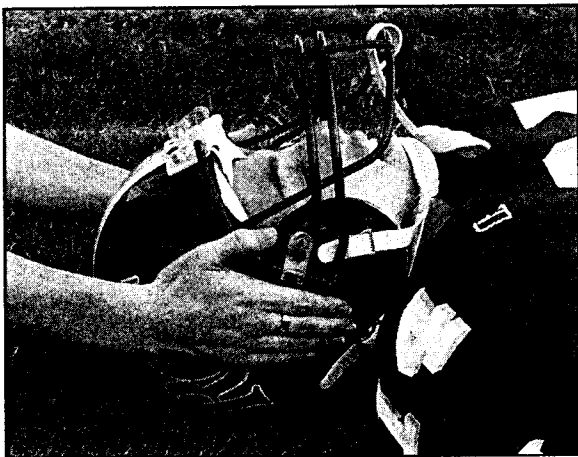


Figure 3. In-line cervical immobilization with the helmet in place. Note that the head is aligned to the torso.

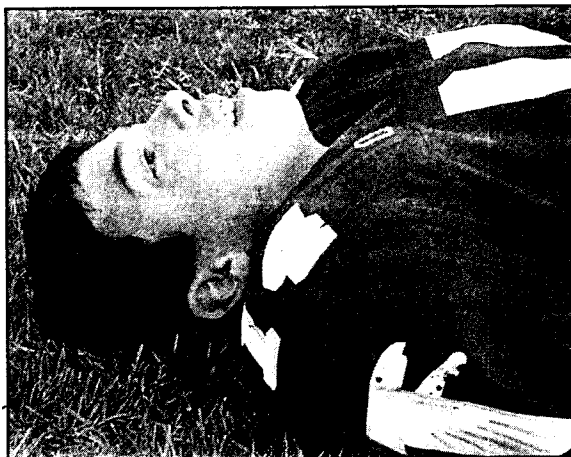

Figure 4. Neck position with the helmet removed. Note that the cervical spine falls into extension due to the shoulder pads elevating the torso.

the rate of recurrence is inversely proportional to the patient's age.³⁶

Anatomy

The shoulder, or glenohumeral joint, is analogous to a ball-and-socket articulation. However, the glenoid is not as deep as a true socket, and the shoulder is often referred to as a "cup resting on a saucer." This lack of bony conformity on the glenoid side makes the shoulder inherently unstable and one of the most commonly dislocated joints in the body. The glenoid labrum is the cartilaginous structure that surrounds the bony glenoid and functions as a restraint for the humeral head. Other soft tissues, such as the rotator cuff muscles and the shoulder capsule, also help to maintain stability in the shoulder.³⁷ Contact injuries that result in shoulder dislocations in young athletes often cause a detachment of the anterior glenoid labrum, which is termed a Bankart lesion (Fig. 5). A Bankart lesion will generally not heal in the appropriate anatomic fashion, which is one factor that predisposes to recurrent dislocations. In addition, the shoulder capsule is stretched during a dislocation, and the resulting capsular laxity often contributes to recurrent dislocation.

Types of Injuries

Shoulder instability results in a spectrum of injuries. For example, a subluxation involves an incomplete separation of the articular surfaces. A dislocation is a more severe injury with com-

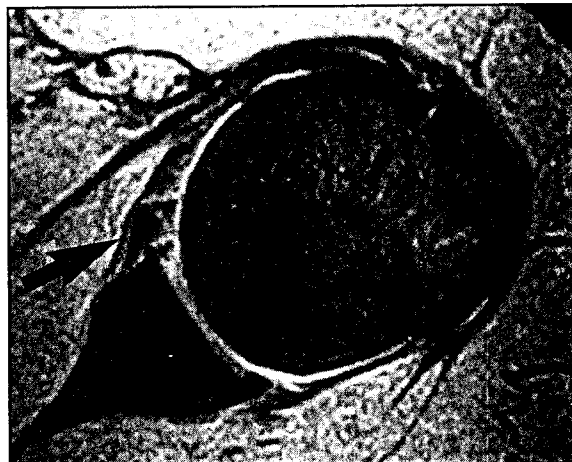


Figure 5. Axial magnetic resonance imaging of the shoulder demonstrating a Bankart lesion (detachment of the anterior labrum from the glenoid), indicated by the black arrow.

plete separation of the humerus from the glenoid.

Dislocations may be classified as anterior or posterior. Anterior shoulder dislocations occur with the arm in the abducted and externally rotated position. This most commonly happens when the athlete attempts to tackle another individual or falls with his or her arm away from the side. Posterior shoulder dislocations occur with the arm adducted and internally rotated. This most commonly occurs in the setting of a fall with the arm extended in front of the patient or when the patient suffers a direct blow on the extended arm. Anterior dislocations are 20 to 80 times more common than are posterior dislocations.

Assessment and Diagnosis on the Field

The history is important in the assessment of a young athlete with a suspected shoulder dislocation. The position of the arm is also important, because it is related to the direction in which the dislocation has occurred. The athlete may also be able to tell the physician whether he or she sensed that the shoulder dislocated completely. In recurrent dislocations with residual ligamentous and capsular laxity, the athlete will often feel the shoulder dislocate and then reduce spontaneously. In some cases, he or she may manipulate the arm to complete a reduction on his or her own. Athletes who have suffered a subluxation may also give a history of feeling the shoulder joint being "out" but then reducing spontaneously. A first-time traumatic glenohumeral dislocation usually stays dislocated until some sort of reduction procedure is performed.

Physical examination may be performed on the field. Athletes with shoulder dislocations will have an obvious deformity. Anterior dislocations result in the humeral head displacing in an anteroinferior direction. This leads to a "squared-off" appearance to the shoulder, because the acromion is prominent without the proximal humerus sitting below it.

Patients with dislocations of the glenohumeral joint are usually unable to actively move their shoulder. Detailed range of motion examinations should not be performed if they cause significant discomfort. A neurovascular examination is critical, because peripheral nerve injuries are not uncommon with shoulder dislocations. Axillary nerve injuries are seen most often in anterior shoulder dislocations.

The main motor function of the axillary nerve is dependent on its innervation of the deltoid muscle. Although patients are generally not in a position to abduct their arm using the deltoid muscle while their shoulder is dislocated, they are able to contract the muscle. With their arm at their side, patients should be instructed to attempt abduction, just enough to allow the muscle to contract. By palpation, the physician can feel the deltoid muscle contract. If present, this demonstrates at least partial function of the nerve.

Sensory function of the axillary nerve comes through the innervation of the so-called "admiral's patch" on the lateral aspect of the shoulder. A difference in sensation from one side to the other may also be related to axillary nerve injury. A detailed neurologic evaluation of the remainder of the upper extremity is also important to rule out other associated injuries or a more proximal neurologic injury.

Radiographic confirmation is the "gold standard" for diagnosis. Without a radiograph documenting the dislocation, it is sometimes impossible to be certain that the shoulder is completely dislocated. Radiographs are also important to rule out an associated fracture of the proximal humerus, glenoid, or clavicle.

The differential diagnosis following an injury to the shoulder of a young athlete includes brachial plexus traction injury, acromioclavicular joint dislocation, fracture of the clavicle or proximal humerus, and cervical spine injury. If cervical spine injury is suspected based on the criteria outlined in the previous section, the appropriate precautions should be employed.

Brachial plexus traction injury, also known as "burners" or "stingers," is extremely common in football but is also seen in other contact sports. This results from forceful depression of the shoulder, which often occurs in tackling. In this situation, the nerve roots are stretched proximally as the shoulder girdle is lowered following contact. These traction injuries often lead to a burning sensation throughout the arm and down into the fingers. This may be accompanied by weakness. Return to play should not be allowed until weakness of the upper limb (usually related to the C5 and C6 nerve roots) is resolved. Nerve root symptoms that are bilateral are related to spinal cord injury until proven otherwise. Stingers are generally unilateral injuries, and neurologic signs or symptoms (eg, tingling, numbness, or weakness) require further investigation when present in both upper extremities or involving the lower extremities.

Dislocations of the acromioclavicular joint, fractures of the clavicle or proximal humerus, or both are common in young athletes. These injuries can be suspected after a detailed clinical examination and confirmed with radiographs.

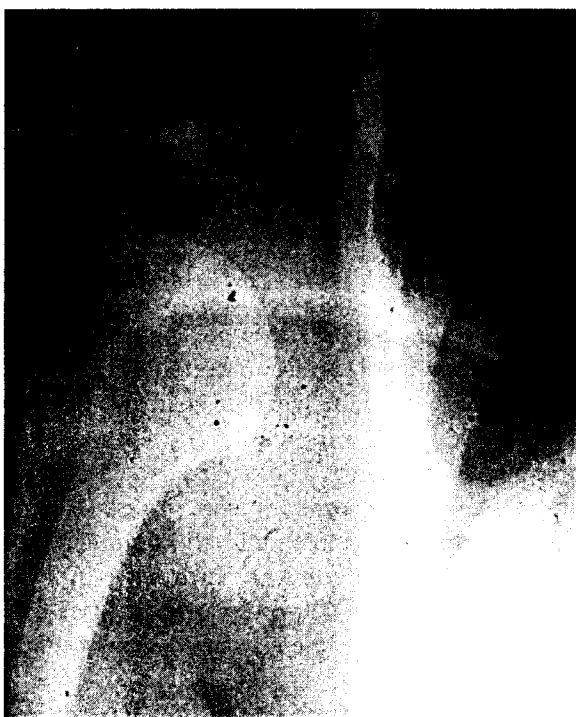

Figure 6. Anteroposterior radiograph of the shoulder demonstrating a glenohumeral dislocation.

Management on the Field

On-field reduction of a dislocated shoulder in a young athlete may be performed by experienced personnel. The advantage of early reduction is that muscle spasm is minimal and the reduction is facilitated. As time passes, the shoulder muscles spasm, leading to a more difficult reduction.

The disadvantage of an on-field reduction is that radiographs are not available to confirm the diagnosis (Fig. 6). Radiographs are required to rule out an associated fracture that may be worsened by a manipulative attempt. Associated fractures of the proximal humerus are more common in elderly patients with osteopenic bone, which is not typical in young athletes. Additionally, the level of trauma imparted to the shoulder while playing sports is generally not as great as in the case of a high-energy injury, such as a motor vehicle accident. Therefore, a dislocation associated with a fracture is relatively uncommon in young athletes, although this injury pattern can occur.

When an athlete has suffered recurrent dislocations of the shoulder and then experiences yet another recurrence, on-field reduction is generally appropriate if experienced personnel are avail-

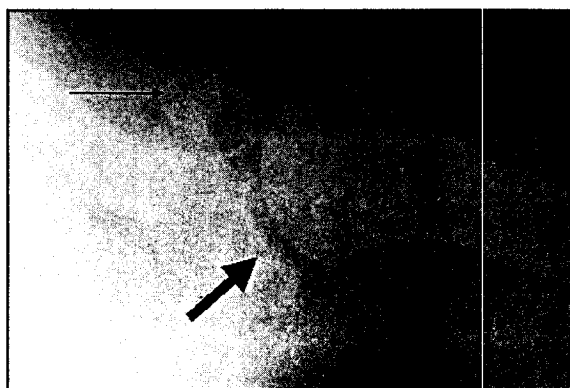


Figure 7. Axillary view of the glenohumeral joint demonstrating the humerus reduced on the glenoid (thick black arrow). The coracoid process (thin black arrow) indicates the anterior aspect of the shoulder, which allows the determination of the direction of the instability, if present.

able. In this case, the risk of displacing an associated fracture is usually outweighed by the benefits of the early reduction.

There are many techniques for reducing shoulder dislocations.³⁸⁻⁴⁰ A detailed description of these methods is beyond the scope of this article. The most commonly employed technique is that of in-line traction. This involves stabilizing the athlete's torso (often using a sheet) and applying in-line traction distally on the arm. The reduction is generally noted by a "clunk" that is felt by both the athlete and the physician. Post-manipulation radiographs must be obtained to confirm the reduction. It is particularly important to obtain an axillary radiograph to confirm the reduction (Fig. 7). Anteroposterior and lateral radiographs by themselves are insufficient to rule out persistent dislocation, particularly in the posterior direction.

Definitive Management

The ultimate management of shoulder dislocations in young athletes typically involves activity modification, bracing, or surgery. As discussed earlier, the rate of recurrence is extremely high in young athletes. Stabilization of first-time dislocations is advocated for athletes younger than 20 years who play contact sports.^{41,42} Individuals who suffer recurrent instability with activities of daily living or at night when trying to sleep are generally also candidates for surgery. Many commercially available braces can be used for athletes who play contact sports and wish to avoid

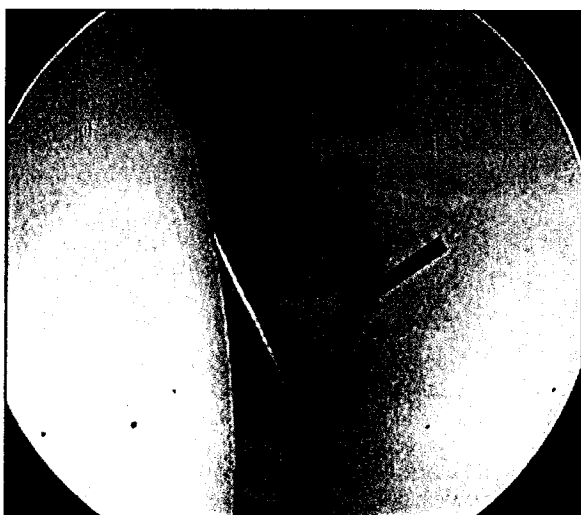

Figure 8. Arthroscopic view of a Bankart lesion. The humeral head is on the left, the glenoid is on the right, and the metal probe is placed between the glenoid and the labrum (black arrow).

surgery to complete their season. These braces function by limiting shoulder motion and therefore not allowing the arm to abduct sufficiently to dislocate. Such braces are, of course, unsatisfactory for athletes who require full mobility of their shoulder for their sport.

Surgical stabilization of the shoulder involves anatomic restoration of the labrum and the capsule using either arthroscopic or open techniques (Fig. 8). The rate of re-dislocation following surgical stabilization is typically less than 10%.⁴³

FRACTURES IN YOUNG ATHLETES

A 12-year-old soccer player was tackled and twisted her leg as she fell. She complains of pain above her ankle and a tibial deformity is obvious.

Types of Injuries

Extremity fractures in children may be incomplete, complete, or epiphyseal. Incomplete fractures are termed "green stick" fractures if they occur due to a bending force and "buckle" fractures if they occur in compression.⁴⁴ Incomplete fractures may occur because the bone is less brittle in the immature skeleton than in the adult skeleton, and young bones often bend before breaking. Complete fractures occur when both cortices break. Epiphyseal fractures involve the growth plate, and are therefore associated with

the potential for growth arrest or the development of a deformity.⁴⁴

Assessment and Diagnosis on the Field

After an assessment of the airway, breathing, and circulation and the level of consciousness has been completed, the physician can focus on the limb.

The athlete should be asked whether he or she has previously injured the area. The mechanism of the current injury is also important. The physician should ascertain whether there was direct contact with another individual or an immovable object (eg, a goalpost). The athlete should also be asked whether he or she heard a "pop" or a "crack." The physician should try to immobilize or splint any suspected fracture, especially if there is an obvious deformity present. This can usually be accomplished with the physician's hands or with the help of another volunteer. Immobilization of the affected part will minimize pain from further movement and may make the on-field examination easier to perform.

If the lower extremity is involved, the physician should determine whether the athlete is able to bear weight, if that is feasible. If the athlete can bear weight, the physician should ask him or her to walk without support. If the athlete is able to do this without difficulty, the physician must decide whether he or she is able to jog and run satisfactorily to return to competition. Athletes who are unable to bear weight without discomfort and have bony tenderness should generally have radiographs performed.

In addition to the injured area, the physician should always examine the joints above and below it. For example, in the lower extremity, the hip and the spine should be examined.

A neurovascular examination should be performed for all extremity injuries. This should include motor and sensory function of the extremity, as well as the pulses. The neurovascular examination should assess the motor power of the distal extremity, sensation, and the color of the skin.

Open fractures are not common in sports. However, they are potentially devastating due to the risk of infection. The physician should check the patient's skin carefully for open wounds at the location of the injury. A fracture may displace

significantly at the time of injury, causing the bone to poke through the skin at a site remote from the fracture. In this case, the patient may have an open wound several inches from the fracture that communicates with the fracture site. The acute management of an open fracture involves applying a sterile dressing to the wound. If a significant deformity is present, the limb should be realigned and a splint applied. If realignment is performed, a neurovascular examination should be done before and after the maneuver.

A patient with an open fracture or a suspected open fracture should receive intravenous antibiotics. Cefazolin is generally the antibiotic of choice unless the patient is allergic. The patient's tetanus status should be updated.⁴⁵

All patients with suspected fractures should not attempt to bear weight if the injury is in the lower extremity. They can be transported on a stretcher or with the use of crutches, as appropriate. The extremity should also be temporarily splinted for the patient's transfer to a facility where an x-ray may be performed.

Indications for ordering an x-ray include deformity or pain following the injury. Radiographs are particularly important to rule out or diagnose fractures. However, other orthopedic conditions, such as tumors or infections that may or may not have been related to the injury, may also be revealed by an x-ray following trauma.

REFERENCES

- Baker C, Kadish H, Schunk JE. Evaluation of pediatric cervical spine injuries. *Am J Emerg Med.* 1999;17:230-234.
- Dietrich AM, Ginn-Pease ME, Bartkowski HM, King DR. Pediatric cervical spine fractures: predominantly subtle presentation. *J Pediatr Surg.* 1991;26:995-1000.
- Kokoska ER, Keller MS, Rallo MC, Weber TR. Characteristics of pediatric cervical spine injuries. *J Pediatr Surg.* 2001;36:100-105.
- McGrory BJ, Klassen RA, Chao EY, Staeheli JW, Weaver AL. Acute fractures and dislocations of the cervical spine in children and adolescents. *J Bone Joint Surg Am.* 1993;75:988-995.
- Clarke KS. Epidemiology of athletic neck injury. *Clin Sports Med.* 1998;17:83-97.
- Torg JS. Epidemiology, pathomechanics, and prevention of athletic injuries to the cervical spine. *Med Sci Sports Exerc.* 1985;17:295-303.
- Fesmire FM, Luten RC. The pediatric cervical spine: developmental anatomy and clinical aspects. *J Emerg Med.* 1989;7:133-142.
- Hensinger R. Spine and spinal cord trauma. In: Reisdorf ER, Wiegstein JG, eds. *Pediatric Emergency Medicine.* Philadelphia: W. B. Saunders; 1993:856-875.
- Pang D, Wilberger JE Jr. Spinal cord injury without radiographic abnormalities in children. *J Neurosurg.* 1982;57:114-129.
- Eleraky MA, Theodore N, Adams M, Rekatte HL, Sonntag VK. Pediatric cervical spine injuries: report of 102 cases and review of the literature. *J Neurosurg.* 2000;92(suppl 1):12-27.
- Rachesky I, Boyce WT, Duncan B, Bjelland J, Sibley B. Clinical prediction of cervical spine injuries in children: radiographic abnormalities. *American Journal of Diseases in Children.* 1987;141:199-201.
- Viccellio P, Simon H, Pressman BD, Shah MN, Mower WR, Hoffman JR. A prospective multicenter study of cervical spine injury in children. *Pediatrics.* 2001;108:E20. Available at www.pediatrics.org/cgi/content/full/108/2/e20.
- Kriss VM, Kriss TC. SCIWORA (spinal cord injury without radiographic abnormality) in infants and children. *Clin Pediatr (Phila).* 1996;35:119-124.
- Leventhal H. Birth injuries of the spinal cord. *J Pediatr.* 1960;56:447.
- Jaffe DM, Binns H, Radkowski MA, Barthel MJ, Engelhard HH 3rd. Developing a clinical algorithm for early management of cervical spine injury in child trauma victims. *Ann Emerg Med.* 1987;16:270-276.
- Finch GD, Barnes MJ. Major cervical spine injuries in children and adolescents. *J Pediatr Orthop.* 1998;18:811-814.
- Schwartz GR, Wright SW, Fein JA, Sugarman J, Pasternack J, Salhanick S. Pediatric cervical spine injury sustained in falls from low heights. *Ann Emerg Med.* 1997;30:249-252.
- Hadley MN, Zabramski JM, Browner CM, Rekatte H, Sonntag VK. Pediatric spinal trauma: review of 122 cases of spinal cord and vertebral column injuries. *J Neurosurg.* 1988;68:18-24.
- Kleiner DA, Bailes JL. Prehospital care of the spine-injured athlete: a document from the Inter-Association Task Force for Appropriate Care of the Spine-Injured Athlete. Presented at the annual meeting of the National Athletic Trainer's Association; 2001; Dallas, TX.
- Huerta C, Griffith R, Joyce SM. Cervical spine stabilization in pediatric patients: evaluation of current techniques. *Ann Emerg Med.* 1987;16:1121-1126.
- Treloar DJ, Nypaver M. Angulation of the pediatric cervical spine with and without cervical collar. *Pediatr Emerg Care.* 1997;13:5-8.
- Boswell HB, Dietrich A, Shiels WE, et al. Accuracy of visual determination of neutral position of the immobilized pediatric cervical spine. *Pediatr Emerg Care.* 2001;17:10-14.
- Curran C, Dietrich AM, Bowman MJ, Ginn-Pease ME, King DR, Kosnik E. Pediatric cervical-spine immobilization: achieving neutral position? *J Trauma.* 1995;39:729-732.
- Herzenberg JE, Hensinger RN, Dedrick DK, Phillips WA. Emergency transport and positioning of young children who have an injury of the cervical spine: the standard backboard may be hazardous. *J Bone Joint Surg Am.* 1989;71:15-22.
- Nypaver M, Treloar D. Neutral cervical spine positioning in children. *Ann Emerg Med.* 1994;23:208-211.
- Hovelius L. Incidence of shoulder dislocation in Sweden.

- Clin Orthop.* 1982;166:127-131.
27. Milgrom C, Mann G, Finestone A. A prevalence study of recurrent shoulder dislocations in young adults. *J Shoulder Elbow Surg.* 1998;7:621-624.
 28. Rowe CR. Prognosis in dislocations of the shoulder. *J Bone Joint Surg Am.* 1956;38:957-977.
 29. Hovelius L. Anterior dislocation of the shoulder in teenagers and young adults: five-year prognosis. *J Bone Joint Surg Am.* 1987;69:393-399.
 30. Hovelius L. Shoulder dislocation in Swedish ice hockey players. *Am J Sports Med.* 1978;6:373-377.
 31. Hovelius L, Augustini BC, Fredin H, Johansson O, Norlin R, Thorling J. Primary anterior dislocation of the shoulder in young patients: a ten-year prospective study. *J Bone Joint Surg Am.* 1996;78:1677-1684.
 32. Hovelius L, Eriksson K, Fredin H, et al. Recurrences after initial dislocation of the shoulder: results of a prospective study of treatment. *J Bone Joint Surg Am.* 1983;65:343-349.
 33. Kazar B, Relovszky E. Prognosis of primary dislocation of the shoulder. *Acta Orthop Scand.* 1969;40:216-224.
 34. McLaughlin HL, Cavallaro WV. Primary anterior dislocation of the shoulder. *J Bone Joint Surg Am.* 1950;32:615-621.
 35. Simonet WT, Melton LJ 3rd, Cofield RH, Ilstrup DM. Incidence of anterior shoulder dislocation in Olmsted County, Minnesota. *Clin Orthop.* 1984;186:186-191.
 36. Marans HJ, Angel KR, Schemitsch EH, Wedge JH. The fate of traumatic anterior dislocation of the shoulder in children. *J Bone Joint Surg Am.* 1992;74:1242-1244.
 37. Pollock RG, Bigliani LU. Glenohumeral instability: evaluation and treatment. *J Am Acad Orthop Surg.* 1993;1:24-32.
 38. Beattie TF, Steedman DJ, McGowan A, Robertson CE. A comparison of the Milch and Kocher techniques for acute anterior dislocation of the shoulder. *Injury.* 1986;17:349-352.
 39. Anderson D, Zvirbulis R, Ciullo J. Scapular manipulation for reduction of anterior shoulder dislocations. *Clin Orthop.* 1982;164:181-183.
 40. Janecki CJ, Shahcheragh GH. The forward elevation maneuver for reduction of anterior dislocations of the shoulder. *Clin Orthop.* 1982;164:177-180.
 41. DeBerardino TM, Arciero RA, Taylor DC. Arthroscopic stabilization of acute initial anterior shoulder dislocation: the West Point experience. *J South Orthop Assoc.* 1996; 5:263-271.
 42. Kirkley A, Griffin S, Richards C, Mitiaci A, Mohtadi N. Prospective randomized clinical trial comparing the effectiveness of immediate arthroscopic stabilization versus immobilization and rehabilitation in first traumatic anterior dislocations of the shoulder. *Arthroscopy.* 1999;15:507-514.
 43. Barron OA, Bigliani LU. Revision instability surgery. *Clin Sports Med.* 1995;14:955-972.
 44. Salter RB. *Textbook of Disorders and Injuries of the Musculoskeletal System: An Introduction to Orthopaedics, Fractures and Joint Injuries, Rheumatology, Metabolic Bone Disease, and Rehabilitation*, 2nd ed. Philadelphia: Williams & Wilkins; 1983.
 45. Green NE, Swiontkowski MF, eds. *Skeletal Trauma in Children*, vol. 3. Philadelphia: W. B. Saunders; 1994.

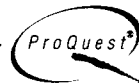How is this publication thinking about the future?

By becoming part of the past. We'd like to congratulate this publication for choosing to be accessible with Bell & Howell Information and Learning.

It is available in one or more of the following formats:

- Online, via the ProQuest® information service
- Microform
- Electronically, on CD-ROM and/or magnetic tape

UMI®
Microform & Print



BELLOHOWELL
Information and Learning

For more information, call

1-800-521-0600, ext 2888 (US) or 01-734-761-4700 (International)

www.bellhowell.infolearning.com