
Results and Survivorship

Analysis of Porous Coated

Anatomic Total Knee

Arthroplasty

R. Marx, MD
J.S. Sampalis, PhD
D.J. Zukor, MD

ABSTRACT: *Seventy-nine primary total knee arthroplasties were performed in 64 patients using the Porous Coated Anatomic prosthesis (PCA, Howmedica, Rutherford, New Jersey). The series was reviewed retrospectively at an average of 50 months follow-up (minimum: 27 months). Kaplan Meyer Survivorship Analysis with Breslow statistic using revision as the end point predicted 89% survivorship of total implants, 92% of tibial components, and 94% of patellar components at 7 years postsurgery. There was no significant difference in the survivorship between the cemented and the cementless prostheses. Medial subsidence of the tibial components was the main problem encountered and was seen primarily in the cementless group. This was the cause of failure in the cementless tibial components and was likely due to varus positioning of the implant at the time of operation. The Hospital for Special Surgery knee*

score was 78 for the overall series and was not significantly different between the cemented and cementless groups.

INTRODUCTION

Total knee arthroplasty (TKA) has proven to be a successful method for reconstruction of the arthritic knee.¹⁹ In the past decade, biologic fixation of the prosthetic components to bone has gained popularity.^{12,19} Cemented TKA consistently has produced excellent results.⁹ Rorabeck et al¹⁷ prospectively compared the short-term clinical results of cemented and cementless TKA and found a higher rate of reoperation and a poorer outcome in the cementless group. Other short-term clinical outcome studies have shown good results with a cementless TKA.^{3,7}

The Porous Coated Anatomic prosthesis (PCA, Howmedica, Rutherford, New Jersey) was introduced in 1980.^{5,6,10} It is a semiconstrained resurfacing system with porous-coated fixation interfaces coated with a double layer of sintered chrome cobalt beads. This interface along with a precise press fit allows the PCA knee to be implanted with or without cement.

This study retrospectively reviews a complete series of PCA total knee arthroplasties clinically and radiographically as well as in terms of implant survivorship.

MATERIALS AND METHODS

At the Royal Victoria Hospital, Montreal, Quebec, from 1983 to 1988, a total of 79 primary PCA TKAs

From the Division of Orthopaedic Surgery, Royal Victoria Hospital, McGill University, Montreal, Quebec, Canada.

Reprint requests: Dr D.J. Zukor, Dept of Orthopaedic Surgery, Sir Mortimer B. Davis Jewish General Hospital, 3755 Cote St Catherine Rd, Montreal, Quebec, Canada H3T 1E2.

TABLE 1

TYPE OF FIXATION USED FOR TIBIAL, PATELLAR, AND FEMORAL COMPONENTS

Component	No. of Knees	
	Cemented	Cementless
Tibial	15	38
Patellar	16	33
Femoral	4	49

TABLE 2

SURVIVORSHIP OF CEMENTED AND CEMENTLESS PATELLAR AND TIBIAL COMPONENTS AT 7 YEARS FOLLOW-UP

Fixation	Type of Component (%)	
	Patellar*	Tibial†
Cemented*	25 (100)	23 (100)
Cementless†	43 (92)	49 (89)
Total	68 (94)	72 (92)

*P = .23 for cemented versus cementless fixation.

†P = .27 for cemented versus cementless fixation.

were performed in 64 patients. Six patients (seven knees) were lost to follow-up, and five patients (six knees) died, leaving 66 knees available for study. Of these, 42 patients (53 knees) were assessed clinically and radiographically by a single independent observer. The remaining 11 patients were interviewed by telephone because of their inability to attend the clinic. Of the 42 patients studied clinically and radiographically, 31 had unilateral and 11 had bilateral arthroplasties. The mean age of the patients was 65 years (range: 30 to 84), and the group was comprised of 9 men and 33 women. The average length of follow-up was 50 months (range: 27 to 82 months). The underlying diagnosis was osteoarthritis in 25 knees, rheumatoid arthritis in 26 knees, posttraumatic arthritis in 1 knee, and pigmented villonodular synovitis in 1 knee. The indication for surgery was disability of the knee due to pain or limited movement. The operations were performed independently by three surgeons.

Clinical evaluation of the patients was performed using the Hospital for Special Surgery (HSS) knee score.⁸ An excellent result is 85 to 100 points, 70 to 84 points is a good result, 60 to 70 points a fair result, and below 60 points was rated as poor.

Kaplan Meyer Survivorship Analysis with Breslow statistic was used for this analysis. Revision of an implant was interpreted as the end-point of survival. All knees were included except for the seven that were lost to follow-up. Of these knees (72), 7 femoral, 25 patellar, and 23 tibial components were cemented.

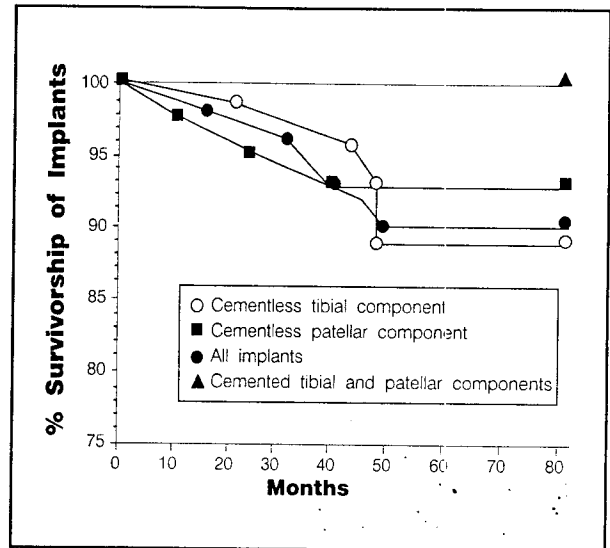


Figure 1. Percentage of survivorship of implants predicted by Kaplan Meyer Survivorship Analysis with Breslow statistic using revision surgery as the end point.

Radiographic assessment used standing anteroposterior views as well as lateral and axial views of each knee.¹³ Parameters assessed included limb and component alignment, radiolucencies, subsidence, lift off, and loose beads. Beads were considered loose when they were totally separated from the surface of the prosthesis on any one view.

Of the 53 knees assessed clinically and radiographically, the tibial component was cemented in 15 knees, the patellar component in 16, and the femoral component in four knees (Table 1). In the majority of cases where cement was used, both the tibial and patellar components were cemented. However, there were five cases in which cement was used only for the tibial component and six cases in which only the patellar component was cemented. Cement was used in cases where it was judged by the surgeon that the bone stock was too poor for immediate press-fit stability. The patient's age also was taken into account with a preference for cementless fixation in younger patients.

A metal-backed patellar component was used routinely. The patella was resurfaced in all but four knees: two having had previous patellectomies and one patient who had bilateral arthroplasties without patellar resurfacing. The original PCA tibial base plates used in this study have medial and lateral fixation studs on the resurfacing tibial component, which are sloped posteriorly by 30°. Tibial component alignment of 3° varus (87°) relative to the long axis of the tibia was attempted in all cases as per the designer's instructions.⁶ A single tibial fixation screw was used for noncemented components, but not for the cemented components.

TABLE 3

COMPLICATIONS

Complication	No.
Aseptic loosening	5*
Urinary tract infections	2
Deep infection	1
Intraoperative fracture of the lateral tibial plateau	1
Wound dehiscence	1
Superficial wound infection	1
Acute pharyngitis	1

*Cementless components—3 tibial and 2 patellar components.

RESULTS

Using revision for septic or aseptic loosening as the end point, life table calculations predict 89% survivorship of total implants, 92% of tibial components, and 94% of patellar components at 7 years postsurgery for the entire series (ie, 72 knees). However, of the tibial and patellar components that were cemented, none required reoperation at the time of follow-up, ie, 100% survivorship. Their cementless counterparts demonstrated 92% patellar component survivorship and 89% tibial component survivorship at 7 years (Figure 1 and Table 2).

The six knees that required reoperation, and were therefore considered failures, were all of the cementless variety. There was one infected prosthesis that was totally revised at 45 months, the pathogen being *Staphylococcus aureus*. Three tibial components were revised for pain with aseptic loosening and medial subsidence at 23, 47, and 48 months. Two patellar components were revised for pain and aseptic loosening at 5 and 26 months. There were no failures attributed to polyethylene wear.¹⁸

Not including the six patients who underwent revision surgery prior to the study and for whom no HSS scores were available, 38 of 47 patients had good or excellent results (81%). Of the patients with fair results (6%) and poor results (12%), most had other medical or arthritic conditions that contributed to a low HSS score due to poor function. For example, a 58-year-old female patient with an HSS score of 57 had very severe generalized rheumatoid arthritis with a right hip girdlestone arthroplasty and a right knee fusion as well as her left TKA. Another patient with poor scores was an 84-year-old man with bilateral TKAs for rheumatoid arthritis at 3 years follow-up. He was institutionalized for other reasons following his joint replacements and went on to develop severe atrophy of both legs to the point where he was unable to walk despite apparently well-functioning total knee replacements.

The average age and follow-up for the cemented arthroplasties was 71 years and 41 months, respectively, compared with 61 years and 61 months for the knees in




Figure 2. Radiograph of a cementless tibial component taken 7 years postsurgery showing medial subsidence of the implant.

which cementless fixation was used. These groups differed significantly for both of these variables ($P < 0.01$). The average HSS score was 78 for the overall group (range: 52 to 95) and was higher in the cementless group than in the cemented group (79 versus 74). This difference was not statistically significant. Table 3 lists the complications that were encountered in the overall series.

There were nine patients who had medial subsidence of their tibial component at follow-up (Figure 2). This was noted at an average of 26 months (range: 9 to 45). Of these, eight were of the cementless variety, and four of these eight went on to require reoperation (Figure 3). In the overall series, immediate postoperative films were available for 32 knees. The average tibial component alignment was 4.8° of varus (range: 0 to 12) in the postoperative period. Of the four patients requiring tibial revision, three had 5° to 7° of tibial component varus postoperatively; the fourth patient's immediate postoperative films were unavailable.

Radiolucencies of 1 mm or more were present in 11 of 38 noncemented tibial components compared with 8 of 15 cemented tibial components at follow-up. Loose beads were noted in 22 of the cementless tibial components and in one of the cemented variety at follow-up. Of the 16 cemented patellar components, 3 showed loose beads and no radiolucencies were present. Of the 33 cementless patellar components, there were 13 cases of

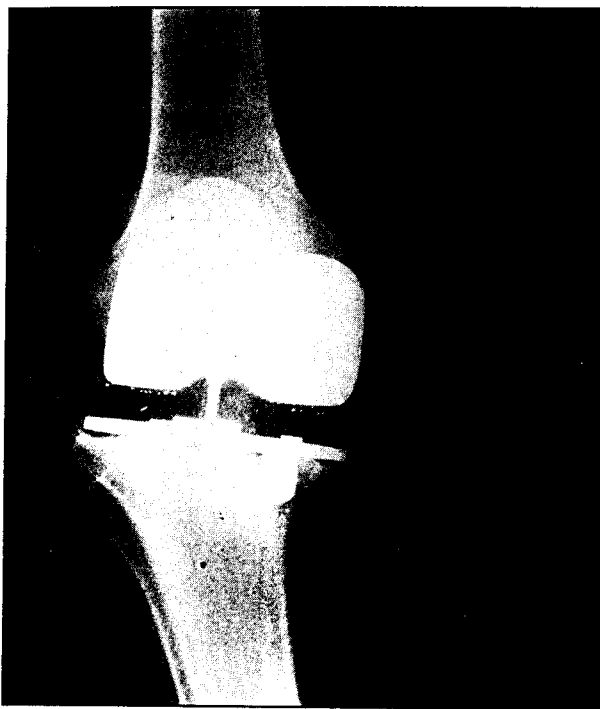


Figure 3. Radiograph of a cementless tibial component taken 47 months postsurgery showing medial subsidence with periprosthetic radiolucencies and evidence of loose beads.

loose beads and 10 cases of radiolucencies (Table 4).

DISCUSSION

Life table calculations predicted 89% survivorship of cementless tibial implants and 92% survivorship of cementless patellar implants at 7 years postsurgery, compared with 100% for cemented components. There was no statistically significant difference between these two groups because of the small sample size, but the difference is clinically relevant. The survivorship for the overall group was 89% at 7 years. This is comparable to the rates found in other large series using several different prostheses.^{11,16}

The two groups of patients in this study are not completely comparable. The patients in the cemented tibial component group were older and had shorter follow-up (both statistically significant). The average HSS score for the entire series was 78 and was not significantly different between the two groups.

The patients with cemented components had poorer bone stock by definition. This decreases the likelihood of achieving superior fixation of the implant. However, these patients also were less active on average because of their older age, therefore placing a lower demand on the implant and the fixation. Moreover, the patients with fair or poor scores had other factors contributing to their low score, eg, severe generalized rheumatoid arthritis, old age, or other medical problems.

TABLE 4

LOOSE BEADS AND RADIOLOCENCIES IN CEMENTED AND CEMENTLESS TIBIAL AND PATELLAR COMPONENTS

	Cemented	Cementless	P Value
Tibial Components*			
Radiolucencies	8 (53%)	11 (29%)	.12
Loose beads	1 (7%)	22 (58%)	.0005
Patellar Components†			
Radiolucencies	0 (0%)	10 (30%)	.02
Loose beads	3 (19%)	13 (39%)	.33

*n = 15 for the cemented components and n = 38 for the cementless components.

†n = 16 for the cemented components and n = 33 for the cementless components.

The main problem encountered with the tibial component in this series was medial subsidence. The Universal Total Knee Instrumentation System (Howmedica, Rutherford, New Jersey) is based on the premise that the proximal tibial shaft is not a reliable alignment reference.⁶ There is a discrepancy of 3° between the mechanical axis of the lower limb (center of the hip to the center of the knee to the center of the ankle) and the vertical axis (perpendicular to the floor). The alignment system accommodates for this discrepancy by requiring a small angle at the proximal transverse tibial cut.⁶ Thus, the 3° of varus that has been built into the tibial alignment system should not put the tibia in varus alignment. However, in practice, tibial component alignment proves to be a problem. The average tibial component alignment in immediate postoperative films was 4.8° of varus (range: 0 to 12). Rand and Bryan found that in attempting to achieve this 3° cut, the average result was 4.5° of varus.¹⁵ This increased tibial component varus predisposes the component to subside on the medial side secondary to increased loading on that side.^{1,2,9,14} There were nine cases of medial subsidence and no cases of lateral subsidence. The three patients who went on to have tibial component failure secondary to medial subsidence (for whom postoperative radiographs were available) had their prostheses implanted in 5° or more of varus.

The incidence of loose beads at follow-up was increased in cementless tibial components compared with cemented components (statistically significant) as well as in the cementless patellar components (not statistically significant). The increased rate of reoperation and loose beads among cementless components indicates inferior fixation among this group. Radiolucent lines (of at least 1 mm) were present in 53% of cemented tibial components compared with 29% of the cementless variety (not statistically significant) and 30% of cementless patellar components versus 0% in cemented patellar implants (statistically significant) (Table 4). These lines have been noted to appear more commonly in cemented tibial

components, possibly because of increased macrophage activity at the cement-bone interface.⁴

CONCLUSION

Our results showed 89% survivorship of implants at 7 years for the entire series. There was no statistically significant difference between the survivorship of the cemented and cementless components. A 3° varus cut of the proximal tibia may lead to increased tibial component varus and subsequent subsidence.

ACKNOWLEDGMENTS

The authors thank Drs Carroll Laurin, Bernard Costello, and William Fisher for allowing the authors to include their patients in this study.

REFERENCES

1. Bargren JH, Blaha JD, Freeman MAR. Alignment in total knee arthroplasty—correlated biomechanical and clinical observations. *Clin Orthop*. 1983;173:178-183.
2. Dorr LD, Boiardo RA. Technical considerations in total knee arthroplasty. *Clin Orthop*. 1986;205:5-11.
3. Eskola A, Vahvanen V, Santavirta S, Honkanen V, Slatis P. Porous-Coated Anatomic (PCA) knee arthroplasty—3 year results. *J Arthroplasty*. 1992;7:223-228.
4. Freeman MAR, Bradley GW, Revell PA. Observations upon the interface between bone and polymethylmethacrylate cement. *J Bone Joint Surg*. 1982;64B:489-493.
5. Hungerford DS, Kenna RV. Preliminary experience with a total knee prosthesis with porous coating used without cement. *Clin Orthop*. 1983;176:95-107.
6. Hungerford DS, Kenna RV, Krackow KA. The porous coated anatomic total knee. *Orthop Clin North Am*. 1982;13:103-122.
7. Hungerford DS, Krackow KA, Kenna RV. Cementless total knee replacement in patients 50 years old and under. *Orthop Clin North Am*. 1989;20:131-145.
8. Insall JN. Total knee replacement. In: Insall JN, ed. *Surgery of the Knee*. New York, NY: Churchill Livingstone; 1984:620-630.
9. Insall JN, Binazzi R, Sondry M, Mestriner LA. Total knee arthroplasty. *Clin Orthop*. 1985;192:13-22.
10. Kenna RV, Hungerford DS. Design rationale for the porous coated anatomic total knee system. In: Hungerford DS, Krackow KA, Kenna RV, eds. *Total Knee Arthroplasty: A Comprehensive Approach*. Baltimore, Md: Williams & Wilkins; 1984:71-88.
11. Knutson K, Lindstrand A, Lidgren L. Survival of knee arthroplasties—a nationwide multicentre investigation of 8000 cases. *J Bone Joint Surg*. 1986;68B:795-803.
12. Landon GC, Galante JO, Maley MM. Noncemented total knee arthroplasty. *Clin Orthop*. 1986;205:49-57.
13. Laurin CA, Dussault R, Levesque HP. The tangential x-ray investigation of the patellofemoral joint: x-ray technique, diagnostic criteria and their interpretation. *Clin Orthop*.

- 1979;144:16-26.
14. Lotke PA, Ecker ML. Influence of positioning of prosthesis in total knee replacement. *J Bone Joint Surg*. 1977;59A:77-79.
15. Rand JA, Bryan RS. Alignment in porous coated anatomic total knee arthroplasty. In: Dorr LD, ed. *The Knee. Papers of the First Scientific Meeting of the Knee Society*. Baltimore, Md: University Park Press; 1985:111-116.
16. Rand JA, Ilstrup DM. Survivorship of total knee arthroplasty—cumulative rates of survival of 9200 total knee arthroplasties. *J Bone Joint Surg*. 1991;73A:397-409.
17. Rorabeck CH, Bourne RB, Nott L. The cemented Kinematic-II and non-cemented porous coated anatomic prostheses for total knee replacement. *J Bone Joint Surg*. 1988;70A:483-490.
18. Tsao A, Mintz L, McRae CR, Stulberg SD, Wright T. Failure of the porous-coated anatomic total knee arthroplasty due to severe polyethylene wear. *J Bone Joint Surg*. 1993;75A:19-26.
19. Vince KG, Insall JN. Long-term results of cemented total knee arthroplasty. *Orthop Clin North Am*. 1988;19:575-580.

EDITORIAL DISCUSSION

KNEE SURGERY: Based on your data, would you recommend continued use of the PCA prosthesis?

Marx et al: No, we would not recommend using the original PCA total knee prosthesis. However, it must be noted that this was one of the earliest cementless prostheses introduced to orthopedic surgeons and that since then, much information has accumulated. In fact, the manufacturer recognized this and modified the design a number of years ago.

The original cementless tibial base plate does not seem to provide adequate fixation. Additionally, for reasons outlined in the article, we believe that attempting to cut the proximal tibia in 3° of varus often predisposes the tibial component to medial subsidence not only because of cutting errors but also because of the relatively tenuous fixation achieved by this original tibial base plate. Therefore, we recommend using a base plate that provides more stable fixation; in fact, we strongly recommend using a cemented tibial component. We also recommend routinely using a 90° tibial cut.

Finally, the issue of metal-backed cementless patellar components has been addressed widely in the literature, and we believe it is now common practice not to use these designs but rather to cement an all-polyethylene patellar component in place if patellar resurfacing is desired.