



This is an enhanced PDF from The Journal of Bone and Joint Surgery

The PDF of the article you requested follows this cover page.

Mycobacterium fortuitum Infection Following Patellar Tendon Repair: A Case Report

Iftach Hetsroni, Howard Rosenberg, Patrick Grimm and Robert G. Marx
J Bone Joint Surg Am. 2010;92:1254-1256. doi:10.2106/JBJS.I.01083

This information is current as of May 18, 2010

Reprints and Permissions

Click here to [order reprints or request permission](#) to use material from this article, or locate the article citation on jbjs.org and click on the [Reprints and Permissions] link.

Publisher Information

The Journal of Bone and Joint Surgery
20 Pickering Street, Needham, MA 02492-3157
www.jbjs.org

Mycobacterium fortuitum Infection Following Patellar Tendon Repair

A Case Report

By Iftach Hetsroni, MD, Howard Rosenberg, MD, Patrick Grimm, BA, and Robert G. Marx, MD, MSc, FRCSC

Investigation performed at the Hospital for Special Surgery, New York, NY

M*ycobacterium fortuitum* is a ubiquitous, rapidly growing mycobacterial species that is infrequently reported in the surgical literature. Clinically important infection with this organism has been described following trauma, injections, augmentation mammoplasty, and ultrasound hydrolipoclasia¹⁻³. In the field of orthopaedic surgery, *Mycobacterium fortuitum* infection has been encountered only following prosthetic arthroplasty or fracture surgery with internal fixation⁴⁻⁹.

We report the case of an otherwise healthy man who underwent patellar tendon repair that was complicated by *Mycobacterium fortuitum* infection. While an accurate diagnosis was delayed by several weeks, aggressive surgical and specific antimicrobial therapy resulted in a favorable outcome. We emphasize the importance of surgeon awareness of this pathogen in order to facilitate accurate diagnosis and appropriate treatment.

The patient was informed that data concerning the case would be submitted for publication, and he consented.

Case Report

A forty-year-old man who worked as an attorney was referred to one of us from another institution two months after surgical repair of the left patellar tendon. Three weeks before the referral, the patient had surgical wound erythema and drainage, accompanied by fever and chills. Oral cephalexin was prescribed but resulted in no improvement. Culture specimens were not obtained at that time. The medical history was otherwise unremarkable. Examination revealed that the patient was 180 cm tall and weighed 95 kg. The systemic temperature, pulse rate, and blood pressure were normal. The patient had an anterior longitudinal left knee incision with diffuse, severe surrounding erythema. The wound was open and draining, with granulation tissue exposed both proximally and in the center. The range of knee motion was from 0° to 70°. The patellar height appeared to be symmetrical on both sides, and the patient could perform an active straight leg raise.

Distal motor and sensory function was normal, with normal pedal pulses. The white blood-cell count was 13,000 cells/ μ L, with a left shift. Magnetic resonance imaging demonstrated joint effusion, bone edema of the patella, extensive edema of the soft tissues surrounding the patella and extending toward the subcutaneous tissues, a draining sinus, and a partial to nearly-full-thickness tear of the patellar tendon (Figs. 1-A and 1-B).

With the patient under anesthesia in the operating room, pus and tissue specimens were obtained from the wound and were sent for Gram staining, bacterial culture, potassium hydroxide preparation, fungal culture, mycobacterial smear and culture, as well as histopathological analysis. At the site of the sutures that had been used for the patellar tendon repair, there was infection tracking into the patella, both at the superior aspect of the patella, where the sutures were tied at the quadriceps tendon insertion, as well as at the inferior pole of the patella, where the sutures had been passed. The wound was irrigated, the sutures were removed, and any nonviable tissue was excised. Manipulation of the knee was performed, and 120° of knee flexion was obtained. The wound was left open, and antibiotic treatment with parenteral vancomycin was initiated. Two days later, a second irrigation and débridement was performed. There was no sign of pus, and the tissue appeared to be viable and clean. As approximately two thirds of the original repair was not intact, the tear in the patellar tendon was repaired with nonabsorbable sutures. At the time of discharge to home, six days after admission, all microbiological studies were negative. A six-week course of ertapenem was prescribed for what was presumed to be a "culture-negative" infection. However, eight days after the first débridement, moderate acid-fast bacilli, which were subsequently identified as *Mycobacterium fortuitum*, were found on mycobacterial culture. The organism's antibiogram became available several weeks later and revealed sensitivity to aminoglycosides, clarithromycin, imipenem, fluoroquinolones, tigecycline, and trimethoprim-sulfamethoxazole. Following the course of ertapenem, the patient received six months

Disclosure: In support of their research for or preparation of this work, one or more of the authors received, in any one year, outside funding or grants in excess of \$10,000 from the Center for Education and Research on Therapeutics, Agency for Healthcare Research and Quality (5 U18-HS016075). Neither they nor a member of their immediate families received payments or other benefits or a commitment or agreement to provide such benefits from a commercial entity.

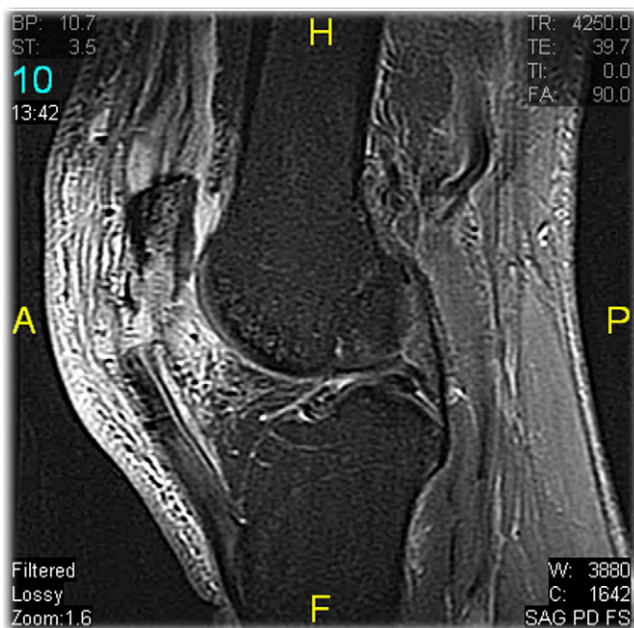


Fig. 1-A

1.5-T magnetic resonance imaging scans demonstrating joint effusion, edema of the patella, edema of the soft tissues surrounding the bone and extending toward the subcutaneous tissues, a sinus, and a partial to nearly-full-thickness tear of the patellar tendon. H = head, F = foot, A = anterior, and P = posterior.

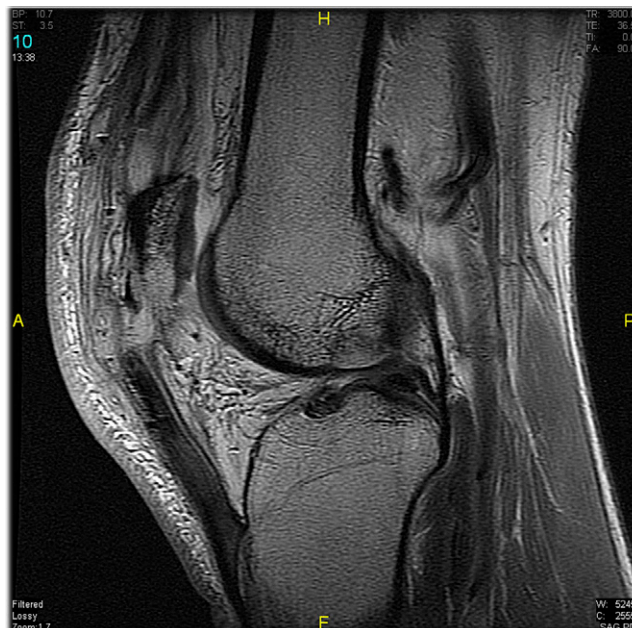


Fig. 1-B

of oral clarithromycin and trimethoprim-sulfamethoxazole. The wound healed well, and the skin sutures were removed twelve days after the second procedure. At the last follow-up visit, seven months following the operations, the patient was doing well and was walking without a limp. The range of knee motion was from 0° to 140°. There were no signs of infection.

Discussion

Mycobacterium fortuitum is an organism that belongs to the group of rapidly growing mycobacteria. It is distributed in natural water, tap water, soil, water-based solutions, and ice and has been described as a contaminant of saline solution, various injectable medications, electromyography needles, and dialysis systems^{1,10,11}.

Infections involving this pathogen often present a therapeutic challenge. The wound infection may present weeks after surgery with dehiscence and sinus tract formation, inconsistently accompanied by fever, chills, or other constitutional symptoms¹². Establishing a microbiological diagnosis will be unlikely if specific mycobacterial media (e.g., Lowenstein-Jensen or Middlebrook 7H11) are not inoculated. Acid-fast stains are often negative. Unrevealing conventional bacterial cultures may be attributed to previous antibiotic therapy if a mycobacterial infection was not considered in the original differential diagnosis. Indeed, previous reports have demonstrated a delay in diagnosis of as much as several months. In a study of a series of rapidly growing mycobacterial skin and soft-tissue infections the median time for microbiological diagnosis after the onset of symptoms was three months², and in another report of a periprosthetic infection the diagnosis was delayed

by fourteen months because a mycobacterial pathogen was not considered¹³.

Although health-care-associated outbreaks have been described, commonly involving exposure to tap water, water-based solutions, and ice machines in hospitals¹⁴, the majority of infections occur sporadically. Infections have been reported in most geographic areas in the world¹⁵, and, in the United States specifically, species of rapidly growing mycobacteria, including *Mycobacterium fortuitum*, have been recovered from 30% to 78% of soil samples throughout the nation^{1,16}.

Treatment of *Mycobacterium fortuitum* infections is often difficult as the organism is resistant to standard antitubercular agents and often to other antibiotics as well. Combination therapy with two or more agents is recommended as monotherapy may be associated with acquired resistance^{1,11}.

In the case of our patient, two months passed from the primary operation until the infection was treated appropriately with aggressive surgery and specific chemotherapy. This scenario of delayed diagnosis and appropriate treatment has been previously reported to result in substantial morbidity or even death^{7,9,17}. Had specimens not been submitted for mycobacterial analysis, our patient may have experienced an adverse outcome. Our decision to manage the patient with combined antimicrobial therapy for six months, according to the culture antibiogram, was based on previous recommendations^{1,8,11} and was successful. The two drugs in this case were selected on the basis of the antibiogram and the desire to administer orally a combination chemotherapeutic regimen that would be well tolerated for an extended period of time (i.e., months). Although fluoroquinolones are often used to treat infections due

to rapidly growing mycobacteria, the well-described risk of tendon inflammation and rupture associated with this drug class proscribed their use in our patient. Nevertheless, as few cases have been reported, no standard protocols are available for the treatment of this pathogen. As such, treatment should be specific for each patient and should rely on early diagnostic studies, culture susceptibility, aggressive surgical débridement, and close clinical monitoring. In cases of periprosthetic infections, removal of the prosthesis should probably be strongly considered^{8,13}.

As to the uniqueness of the case described, it should be noted that, in the orthopaedic literature, *Mycobacterium fortuitum* has only been reported in association with knee and hip arthroplasty, open fractures, and, in one case, a closed tibial fracture that was treated with an intramedullary nail^{14-9,13}. The case described here is exceptional as *Mycobacterium fortuitum* infection was found following a soft-tissue procedure in an otherwise healthy patient. In view of this case and reports in the literature demonstrating serious potential complications related to this undiagnosed infection, we believe that the cost and morbidity of an overlooked diagnosis justify that aerobic

and anaerobic cultures be universally accompanied by mycobacterial cultures at the time of débridement of musculoskeletal infections. ■

Iftach Hetsroni, MD
Orthopaedic Department, Meir General Hospital,
Sapir Medical Center, Tsharnichovski Street 59,
Kfar Saba 44281, Israel

Howard Rosenberg, MD
Division of Infectious Diseases,
Weill Cornell Medical Center, 525 East 68th Street,
Room A-421, New York, NY 10065

Patrick Grimm, BA
Robert G. Marx, MD, MSc, FRCSC
Hospital for Special Surgery, 535 East 70th Street,
New York, NY 10021.
E-mail address for R.G. Marx: MarxR@hss.edu

References

1. Brown-Elliott BA, Wallace RJ Jr. Clinical and taxonomic status of pathogenic nonpigmented or late-pigmenting rapidly growing mycobacteria. *Clin Microbiol Rev.* 2002;15:716-46.
2. Usian DZ, Kowalski TJ, Wengenack NL, Virk A, Wilson JW. Skin and soft tissue infections due to rapidly growing mycobacteria: comparison of clinical features, treatment, and susceptibility. *Arch Dermatol.* 2006;142:1287-92.
3. Herreros FO, Velho PE, De Moraes AM, Cintra ML. Cutaneous atypical mycobacteriosis after ultrasound hydrolipoclasia treatment. *Dermatol Surg.* 2009;35:158-60.
4. Booth JE, Jacobson JA, Kurrus TA, Edwards TW. Infection of prosthetic arthroplasty by *Mycobacterium fortuitum*. Two case reports. *J Bone Joint Surg Am.* 1979;61:300-2.
5. Herold RC, Lotke PA, MacGregor RR. Prosthetic joint infections secondary to rapidly growing *Mycobacterium fortuitum*. *Clin Orthop Relat Res.* 1987;216:183-6.
6. Delrieu F, Slaoui O, Evrard J, Amor B, Postel M, Kerboull M. [Mycobacterial infection of the hip following total prosthesis. Study of 6 cases]. *Rev Rhum Mal Osteoartic.* 1986;53:113-8. French.
7. Ohry A, Brooks M, Steinbach T, Rozin R. Osteomyelitis caused by *Mycobacterium fortuitum*. *Infection.* 1977;5:46-8.
8. Cheung I, Wilson A. *Mycobacterium fortuitum* infection following total knee arthroplasty: a case report and literature review. *Knee.* 2008;15:61-3.
9. Hasegawa T, Watanabe R, Hayashi K, Inufusa A, Nakagawa H. Postoperative osteomyelitis due to *Mycobacterium fortuitum*. A case report. *Arch Orthop Trauma Surg.* 1992;111:178-80.
10. McFarland EJ, Kuritzkes DR. Clinical features and treatment of infection due to *Mycobacterium fortuitum/chelonae* complex. *Curr Clin Top Infect Dis.* 1993;13:188-202.
11. Brown TH. The rapidly growing mycobacteria—*Mycobacterium fortuitum* and *Mycobacterium chelonae*. *Infect Control.* 1985;6:283-8.
12. Kalita JB, Rahman H, Baruah KC. Delayed post-operative wound infections due to non-tuberculous mycobacterium. *Indian J Med Res.* 2005;122:535-9.
13. Saccente M. *Mycobacterium fortuitum* group periprosthetic joint infection. *Scand J Infect Dis.* 2006;38:737-9.
14. Wallace RJ Jr, Brown BA, Griffith DE. Nosocomial outbreaks/pseudo-outbreaks caused by nontuberculous mycobacteria. *Annu Rev Microbiol.* 1998;52:453-90.
15. Martín-Casabona N, Bahrmand AR, Bennedsen J, Thomsen VO, Curcio M, Fauville-Dufaux M, Feldman K, Havelkova M, Katila ML, Köksalan K, Pereira MF, Rodrigues F, Pfyffer GE, Portaels F, Urgell JR, Rüscher-Gerdes S, Tortoli E, Vincent V, Watt B; Spanish Group for Non-Tuberculosis Mycobacteria. Non-tuberculous mycobacteria: patterns of isolation. A multi-country retrospective survey. *Int J Tuberc Lung Dis.* 2004;8:1186-93.
16. O'Brien RJ, Geiter LJ, Snider DE Jr. The epidemiology of nontuberculous mycobacterial diseases in the United States. Results from a national survey. *Am Rev Respir Dis.* 1987;135:1007-14.
17. Kuritsky JN, Bullen MG, Broome CV, Silcox VA, Good RC, Wallace RJ Jr. Sternal wound infections and endocarditis due to organisms of the *Mycobacterium fortuitum* complex. *Ann Intern Med.* 1983;98:938-9.