

Volume 17
Issue 3
July 2009

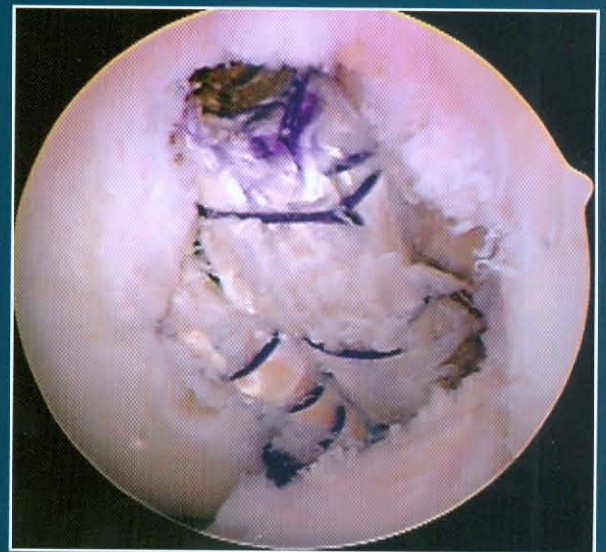guest editor:

Gregory C. Fanelli, MD


How the Experts Manage PCL Injuries

Operative Techniques in Sports Medicine

editors: David Drez, Jr., MD
Jesse C. DeLee, MD



www.optechsportsmed.com



Management of Posterior Cruciate Ligament Injuries

Robert G. Marx, MD, Michael K. Shindle, MD, and Russell F. Warren, MD

Diagnosis and management of posterior cruciate ligament tears has advanced over the past 2 decades due to improved understanding of the natural history of injury and basic science principles. Despite the current advances, our understanding of posterior cruciate ligament injury and treatment continues to lag behind that of the anterior cruciate ligament. In addition, there is still controversy regarding indications for surgical intervention, use of 1 vs 2 reconstructive graft bundles, location of the femoral tunnels, and the ideal degree of graft tensioning. The purpose of this article is to present our diagnostic and surgical preferences.

Oper Tech Sports Med 17:162-166 © 2009 Elsevier Inc. All rights reserved.

KEYWORDS PCL, knee arthroscopy, transtibial

Diagnosis

Evaluation of a knee injury should begin with a thorough history, including obtaining the mechanism of injury to determine the direction of the applied force. The classic mechanism of injury to the posterior cruciate ligament (PCL) is an anterior blow to the proximal tibia that may be associated with a “dashboard injury” during a motor vehicle accident or in sports due to a fall on a flexed knee with the foot in plantar flexion. A PCL injury can be partial or complete and it can be isolated or involve multiple ligaments.

A physical examination should be performed systematically and include an evaluation of the patient’s lower extremity alignment, gait, inspection for any swelling or deformity, palpation of the joint, range of motion, and then testing for instability and other injuries. The posterior drawer test is the most sensitive test for PCL deficiency and is performed with the tibia held in a neutral position; the knee is flexed to 90° and the hip 45°, whereas a posterior force is applied to the proximal tibia. In a normal knee, the medial tibial plateau is usually 1 cm anterior to the medial femoral condyle. In an acute injury, the patient may not be able to flex the knee to 90°; thus, this test may have limited utility in the acute setting. A grade 1 injury has less than 5 mm of displacement compared with the contralateral side, and the tibia is anterior to the femoral condyles. A grade 2 injury has 5-10 mm of displacement, and the tibia is flush with the condyles. A grade 3 injury has more than 10 mm of displacement and the

tibia is posterior to the condyles. Grade I and II injuries are considered partial PCL tears, and grade III injuries are considered complete PCL tears and may indicate a concomitant injury to the posterolateral corner. We believe that the traditional grading system for the posterior drawer of 1+, 2+, and 3+ is inherently ambiguous because it relies on the subjective estimation by the examiner of several millimeters of posterior translation of the tibia on the femur. Thus, we have devised a more simplified clinical grading system on the basis of the assessment of the posterior drawer test performed with the knee in 90° of flexion. The grading system is normal: no loss of tibial offset; grade A: slight loss of tibial offset when applying force to the tibia with the knee at 90° of flexion; grade B: the tibia is flush with the femur; and grade C: the tibia is able to be displaced behind the femur. Grade A is defined as a partial tear and grade B as a complete PCL tear. Grade C PCL injuries are frequently associated with additional injury to the posterolateral corner or the medial aspect of the knee.¹

In the setting of a PCL injury, special attention must be undertaken when evaluating the anterior cruciate ligament (ACL). When assessing the ACL when the proper tibial-femoral relationship is not restored, the examiner may falsely attribute an increase in anterior-posterior laxity to a torn ACL. The Lachman test will show increased translation with a good endpoint anteriorly. Whether the Lachman test has a poor endpoint and increased translation, an ACL and PCL injury may be present.

Posterolateral injury is noted by opening on varus stressing in flexion and extension. In addition, the dial test can be performed to evaluate posterolateral spin. Greater than 10°-15° of external rotation compared with the contralateral side at 30° and 90° indicates a combined PCL and posterolateral

Department of Orthopedic Surgery, Hospital for Special Surgery, New York, NY. Address reprint requests to Michael K. Shindle, MD, Hospital for Special Surgery, 535 E 70th Street, New York, NY 10021. E-mail: shindlem@hss.edu

corner injury. Another test that is used is the posterolateral spin test using step-off of the lateral tibial plateau from the lateral femoral condyle. With the knee flexed at 30° or 90° the step-off of the lateral tibial plateau from the lateral femoral condyle can be palpated with the examiner's thumb to determine the amount of posterolateral spin compared with the normal side. By examining posterior lateral rotation at the knee we avoid measurement error due to rotation of the tibia, ankle, or foot that can occur with the dial test. Postero-medial injury is noted by valgus opening in flexion and extension. With chronic injuries, patellofemoral and medial compartment tenderness may be present secondary to degenerative changes.

Patient Selection

In general, acute isolated grade A and B PCL injuries can be treated nonoperatively. With our experience, the subsequent operative rate is less than 10%.¹ In grade C injuries with associated ligament pathology, we recommend repairing or reconstructing all ligaments. PCL avulsions may be present and can be repaired primarily in some cases with an arthroscopic technique and suture repair through drill holes.

When evaluating chronic PCL injuries for surgical intervention, long leg radiographs are used to rule out malalignment, and gait should be assessed for the presence of a dynamic thrust if there is posterolateral injury. Some chronic PCL injuries develop medial osteoarthritis, and thus a bipplanar osteotomy that increased the tibial slope may be helpful.

Acute vs Chronic

With acute injuries, one has to worry about a posterolateral injury with an associated peroneal nerve injury. A stretch neuropraxia is the common mechanism of injury, but complete nerve transection has been reported. The outcome of nerve recovery is unpredictable with no recovery reported in more than 50% of injuries.² The peroneal nerve is the most common nerve injury during a knee dislocation because there is only 0.5 cm of excursion of the peroneal nerve at the fibular head during knee motion.

Also, for PCL injuries associated with a knee dislocation, one has to assess neurovascular function. A clinical pulse examination as well as an ankle-brachial index should be performed. Patients with an ankle-brachial index less than 0.90 should have an arteriography performed.³ If properly performed and interpreted, magnetic resonance angiography is a noninvasive alternative to standard arteriography but further studies are warranted.⁴ Emergent vascular reconstruction with a reverse saphenous vein graft is the treatment of choice for an ischemic limb.⁵

Surgical Timing

If there is a multiligament knee injury that is reduced but that has gross instability on examination, surgery at 7-10 days is appropriate. At our institution, patients are occasionally referred with an external fixator or vascular repair already per-

formed. In this situation, we prefer to leave them in the external fixator for 5-6 weeks. The external fixator is then removed, and a rehabilitation program is initiated. In our experience, some patients scar in and do not require further surgical intervention.

Preferred Surgical Technique

Presently, we are using an arthroscopic approach for isolated PCL injuries with a transtibial approach. Fluid extravasation and compartment syndrome are potential complications so the use of gravity flow for some acute cases is recommended instead of a fluid pump. To visualize the torn PCL, a 70 degree arthroscope is placed in the posterior medial compartment of the knee. We establish a postero-medial portal under direct visualization while transilluminating the postero-medial corner. A periosteal elevator or an arthrocare device is then used to elevate the posterior capsule off the tibia that should be dissected 2.5 cm distally to have adequate visualization to ensure the tunnel is low enough for anatomic reconstruction. A combination of shaver and arthrocare device is also used in the postero-medial portal to debride the tibial stump of the torn PCL and must be directed anteriorly at all times. A 15-mm offset PCL guide set is used at 50°-55° through the antero-medial portal placed on the distal and lateral aspect of the PCL tibial insertion site. A 3/32 Kirchner wire is then advanced under direct fluoroscopic guidance using lateral images. The guidewire should exit the posterior tibial cortex approximately 20 mm below the tibial plateau, and a curette should be placed directly over the guidewire at the site of tibial PCL insertion when drilling is performed. The femoral tunnel is then created, and one author (R.F.W.) prefers the double bundle technique for the femur and the other author (R.G.M.) prefers a single bundle technique. There is no data to suggest improved long-term clinical outcomes with either technique. However, Harner et al⁶ performed a cadaveric study that has suggested that a double-bundle PCL reconstruction can more closely restore the biomechanics of the intact knee.

For the single-bundle reconstruction, the goal is to simulate the larger and stiffer anterolateral bundle (ALB) of the PCL so the femoral tunnel is positioned at the center of the ALB and approximately 7 mm off the articular margin.⁷ The femoral tunnel can be created either with an outside-in or inside-out approach. For the inside-out technique the femoral guidewire is inserted through the anterolateral portal and overdrilled with an 11 mm compaction drill to a depth of 25-30 mm. A 3.2 mm drill bit is then used to create an exit hole out of the medial femur to allow graft passage and tensioning during fixation. For the outside-in method, we use a sub-vastus technique with a slightly medial longitudinal incision over the medial head of the vastus. Dissection is then carried directly down to the fascia that is divided over the vastus medialis followed by blunt dissection to elevate the vastus medialis laterally off the femur. An elevator is then placed under the vastus medialis retracting it laterally to allow easy access to the femur without injuring the muscle fibers of the vastus medialis.

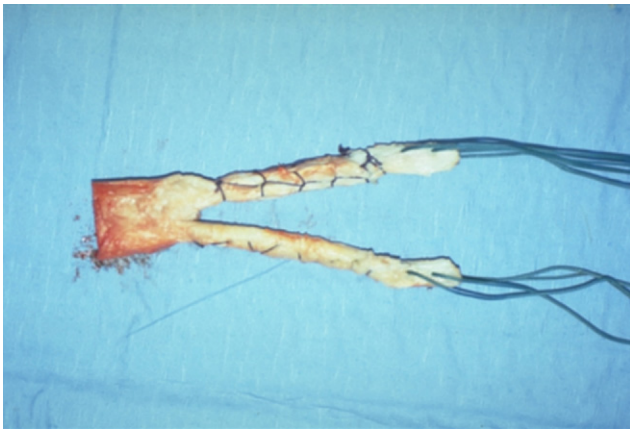


Figure 1 Achilles tendon allograft for a tibial inlay technique demonstrating the calcaneal bone plug and whip-stitches in the tendinous portion of the allograft.

The Achilles tendon allograft is then prepared. For single bundle technique, the calcaneal bone plug is prepared to a size 11 mm. Three drill holes are created in the bone plug and number 2 orthocord or fiberwire is placed. A baseball whip-stitch also using number 2 orthocord or fiberwire is placed in the tendinous portion of the Achilles allograft (Fig. 1).

We then place a switching stick through the postero-medial portal to act as a pulley to pass the graft as well as surgical lubrication to facilitate graft passage (Fig. 2). A 20 gauge wire loop is passed through the tibial tunnel, and a grasper is used through the anterolateral portal. The femur is fixed with a single metal interference screw, and on the tibial side we use back up fixation, including a bio-absorbable screw along with a soft tissue washer or if the graft is short, we tie around a suture post in addition to the interference screw. The knee is cycled while applying tension to the graft before tibial fixation. The knee is held in 90° of flexion and an anterior drawer force is applied during final fixation.

For double bundle reconstruction, a 8 or 9 mm femoral tunnel for the ALB is placed as previously discussed, and then a 7 mm diameter femoral tunnel is placed within the PCL footprint inferior to and slightly deeper in the intercondylar notch than the anterolateral tunnel. A bone bridge of at least 5 mm needs to be preserved. The postero-medial bundle is tensioned with an anterior drawer force applied with the tibia near full extension and the posterolateral bundle with 90° of knee flexion.

The tibial inlay technique is reserved for revision procedures for the PCL. In our experience, the extra surgical time, dissection, and morbidity have not been associated with improved results in the primary setting.⁸

Graft Selection

Generally, we have used Achilles tendon allografts for these reconstructions. The advantages of the allograft include the avoidance of donor site morbidity, decreased surgical time, and tissue availability in cases of double-bundle PCL reconstruction, combined ligamentous injury, and revision sur-

gery. Disadvantages include the increased cost and risk of disease transmission.

Concomitant Injuries

Up to 60% of PCL injuries involve associated injuries to the posterolateral corner, so a thorough evaluation is critical because failure to restore the integrity of the posterolateral corner will lead to excessive force on a reconstructed PCL graft. In the acute setting, we generally augment our repairs with allograft tissue.⁹ The approach uses a 12-18 cm incision that begins midway between the fibular head and Gerdy's tubercle and then continues proximally over the lateral epicondyle to parallel the posterior border of the iliotibial band. On the posterior border of the biceps femoris the peroneal nerve should be identified and protected with a vessel loop. The interval is then developed between the posterior border of the iliotibial band and the anterior border of the biceps femoris. In acute injuries, direct suture repair of the injured structures is performed from deep to superficial. In chronic injury, we prefer to reconstruct the lateral collateral ligament or the popliteofibular ligament using a fibular based technique.¹⁰

For a combined ACL/PCL reconstruction, we prefer to set the tunnels for the tibia and the femur first for the PCL followed by the ACL. Both pins are placed in the tibia and confirmed with fluoroscopy. The grafts are placed for both, and the offset is created first by tensioning the posterior bundle near full extension and the ALB at 90°. For single bundle PCL reconstruction the graft is tensioned with the knee in 90° of flexion to tension the ALB which has been shown to have greater linear stiffness and ultimate load than both the postero-medial component and meniscofemoral ligaments.¹¹ The ACL is then tensioned at 30° knee flexion (RFB) or near full extension (RGM) according to surgeon preference.

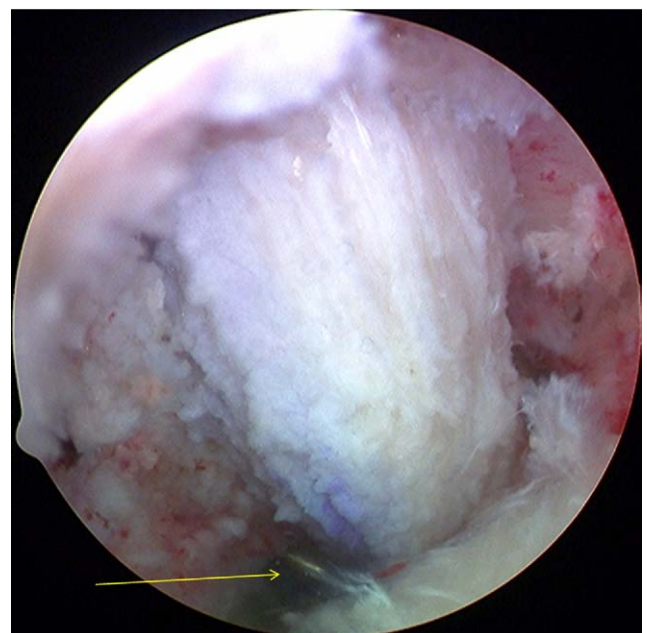


Figure 2 Arthroscopic image demonstrating a switching stick being used in the postero-medial portal to act as a pulley to pass the graft.

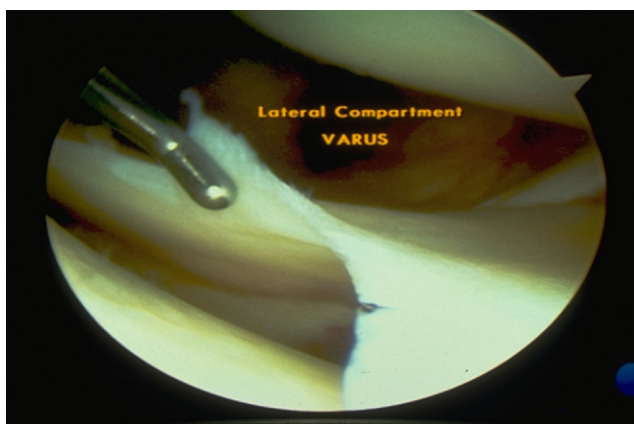


Figure 3 Arthroscopic image of the lateral compartment with a varus stress applied. There is >10 mm of opening, thus reconstruction of the collateral ligaments is indicated.

In chronic cases, it is often difficult to determine the need for surgical intervention for collateral ligament injuries. When there is an increased laxity that is notable compared with the normal knee, we generally reconstruct the collateral ligaments to avoid increased stress on the PCL graft. This can be measured at the time of surgery in the chronic cases where it is not obvious as to the amount. With a varus or valgus stress applied during arthroscopy, medial or lateral joint space opening estimated with a probe more than 6 mm indicates that there has been some stress in the collateral system. When there is 8-10 mm of opening, reconstruction of the collateral ligaments is indicated (Fig. 3).

Rehabilitation

For isolated grade I and II PCL injuries treated nonoperatively, patients undergo protected weight bearing and quadriceps muscle rehabilitation. Return to sport can be at 2-4 weeks if the patient is pain free and obtains full knee range of motion. For grade III PCL injuries treated nonoperatively, patients are splinted in extension for 2-4 weeks to prevent posterior tibial translation secondary to gravity and hamstring contraction. After this period of immobilization, rehabilitation progresses as with grade I and II PCL injuries and return to sports can be expected 10-12 weeks after the initial injury.

For postoperative PCL reconstruction, physical therapy initially consists of reestablishing knee motion, reducing inflammation, and emphasizing quadriceps strengthening. The knee is braced in extension for 4-6 weeks but partial weight bearing is performed and quadriceps exercises may begin immediately. Motion of the isolated PCL reconstruction is delayed until 4 weeks. Closed chain exercises may begin at 6 weeks. The key to postoperative rehabilitation for these injuries is to be patient with range of motion. For instance, with multiligamentous reconstructions it is acceptable for the patient to have only 90° of flexion at 3 months after surgery as long as progress in being made. A slower recovery often leads to a better result because patients who recover motion early

often stretch out their graft. Hamstring exercises are delayed for 4 months because this may place excessive posterior loads on the tibia. When strength is adequate, light jogging begins at 6 months and return to play is allowed 9-12 months after surgery.

Return to Sport

For isolated grade I and II PCL injuries that are treated conservatively, return to sport is usually allowed within 2-4 weeks after injury if recovery is adequate after a period of protected weight-bearing and quadriceps muscle rehabilitation. For grade III injuries treated nonoperatively, return to sports is delayed for 10-12 weeks and includes a 4-week period of immobilization and then 8 weeks of rehabilitation and quadriceps strengthening. Most athletes who maintain strength return to sports without functional disability.¹²

Results

A retrospective review of 29 isolated PCL reconstructions was performed at our institution between 1980 and 1997.⁸ Overall, 90% of patients were satisfied with their surgery. The surgical procedures included 13 traditional endoscopic transtibial PCL reconstructions [9 bone-patellar tendon-bone autograft (BPTB), 2 BPTB allograft, and 2 allograft Achilles tendon] and 7 transtibial inlay (all BPTB, 5 allograft, and 2 autograft). When comparing the traditional endoscopic reconstructions with the tibial inlay technique, there were no significant differences in KT-1000, posterior drawer testing, functional testing or Lysholm, Tegner, and AAOS scores at a minimum 2 year follow-up.

Recent Changes in PCL Protocol

In the 1990s, we used the tibial inlay technique and subsequently switched to doing an arthroscopic tibial tunnel combined with a single or double femoral reconstruction. The tibial inlay technique is now reserved for revision procedures. With concomitant posterolateral reconstructions we are using a fibular based reconstruction.¹⁰ For a concomitant postero-medial reconstruction, we are using a semitendinosus autograft or an Achilles tendon allograft.

References

1. Patel DV, Allen AA, Warren RF, et al: The nonoperative treatment of acute, isolated (partial or complete) posterior cruciate ligament-deficient knees: An intermediate-term follow-up study. *HSS J* 3:137-146, 2007
2. Goitz RJ, Tomaino MM: Management of peroneal nerve injuries associated with knee dislocations. *Am J Orthop* 32:14-16, 2003
3. Mills WJ, Barei DP, McNair P: The value of the ankle-brachial index for diagnosing arterial injury after knee dislocation: A prospective study. *J Trauma* 56:1261-1265, 2004
4. Potter HG, Weinstein M, Allen AA: Magnetic resonance imaging of the multiple-ligament injured knee. *J Orthop Trauma* 16:330-339, 2002

5. Fanelli GC, Orcutt DR, Harris JD, et al: Multiple ligament injuries of the knee, in Tornetta P, Einhorn TA (eds): Sports Medicine. Philadelphia, PA, Lippincott Williams & Wilkins, 2006, pp 376-390
6. Harner CD, Janaushek MA, Kanamori A, et al: Biomechanical analysis of a double-bundle posterior cruciate ligament reconstruction. *Am J Sports Med* 28:144-151, 2000
7. Rihn JA, Gause P, Cunningham R, et al: Posterior cruciate ligament injuries, in Tornetta P, Einhorn TA (eds): Sports Medicine. Philadelphia, PA, Lippincott Williams & Wilkins, 2006, pp 363-390
8. Macgillivray JD, Shubin Stein BE, Park M, et al: Comparison of tibial inlay versus transtibial techniques for isolated posterior cruciate ligament reconstruction: Minimum 2-year follow-up. *Arthroscopy* 22:320-328, 2006
9. Noyes FR, Barber-Westin SD: Surgical reconstruction of severe chronic posterolateral complex injuries of the knee using allograft tissues. *Am J Sports Med* 23:2-12, 1995
10. Schechinger SJ, Levy BA, Dajani KA, et al: Achilles tendon allograft reconstruction of the fibular collateral ligament and posterolateral corner. *Arthroscopy* 25:232-242, 2009
11. Harner CD, Xerogeanes JW, Livesay GA, et al: The human posterior cruciate ligament complex: An interdisciplinary study. Ligament morphology and biomechanical evaluation. *Am J Sports Med* 23:736-745, 1995
12. Parolie JM, Bergfeld JA: Long-term results of nonoperative treatment of isolated posterior cruciate ligament injuries in the athlete. *Am J Sports Med* 1:35-38, 1986