

Case Report Étude de cas

SLIPPED CAPITAL FEMORAL EPIPHYSIS AFTER SEPTIC ARTHRITIS OF THE HIP IN AN ADOLESCENT: REPORT OF A CASE

Robert G. Marx, MD, MSc; James G. Wright, MD, MPH

Septic arthritis of the hip must be managed promptly to avoid the serious complications associated with the condition. In the case reported here, the diagnosis was delayed and was complicated by a slipped capital femoral epiphysis. The patient, an adolescent boy previously in good health, presented with a 2-week history of hip pain and systemic illness. Septic arthritis was diagnosed and was managed by incision and drainage and antibiotic therapy. Two weeks later he presented with a subcutaneous abscess and a slipped capital femoral epiphysis, which was pinned in situ. There was a 2.5-cm leg-length discrepancy. Avascular necrosis of the femoral head subsequently developed leaving the boy with a permanent disability.

Il faut traiter rapidement l'arthrite aiguë suppurée de la hanche afin d'éviter les complications sérieuses associées à cet état. Dans le cas décrit ici, le diagnostic a été posé en retard et a été compliqué par une luxation de l'épiphyse de la tête du fémur. Le patient, un adolescent auparavant en bonne santé, se plaignait d'avoir une douleur à la hanche et des malaises depuis deux semaines. On a diagnostiqué une arthrite aiguë suppurée qui a été traitée par incision et drainage, et administration d'antibiotiques. Deux semaines plus tard, il s'est présenté avec un abcès sous-cutané et une luxation de l'épiphyse de la tête du fémur, qui a été fixée in situ. Le patient avait une jambe plus longue que l'autre de 2,5 cm. Une nécrose vasculaire de la tête du fémur a fait son apparition par la suite et causé à l'adolescent une incapacité permanente.

Septic arthritis of the hip is associated with devastating complications if not treated promptly.^{1,2} These complications include osteomyelitis of the proximal femur, growth arrest of the proximal femur with resulting limb-length discrepancy, coxa magna, coxa vara, pathologic dislocation, avascular necrosis of the femoral head and arthrosis.²⁻⁵ Epiphysiolysis or epiphyseal separation after septic arthritis has been reported in infants. Most of these reports were published in the preantibiotic era,^{6,7} or in the early 1960s⁸⁻¹⁰ before urgent arthrotomy be-

came the standard treatment for acute septic arthritis. We describe a case of slipped capital femoral epiphysis, previously unreported, complicating delayed treatment of septic arthritis of the hip in an adolescent boy.

CASE REPORT

A 13-year-old boy, who was previously in good health, sustained a painful blow to his right hip while playing hockey. He was able to continue playing but had continued hip pain causing him to limp. Three days

after the injury a fever developed (body temperature, 38.3 °C). The next day he sought medical help. His family physician diagnosed a muscle strain and prescribed acetaminophen and codeine for the pain.

The boy's fever persisted over the next 10 days and his pain increased. Consultations with an orthopedic surgeon and another family physician supported the diagnosis of a muscle strain of the hip. Fourteen days after the injury, the boy presented to the emergency department of his local hospital. He was referred to The Hos-

From the Division of Orthopedic Surgery, The Hospital for Sick Children, Toronto, Ont.

Accepted for publication Nov. 11, 1997.

Correspondence to: Dr. James G. Wright, S 107, Division of Orthopedic Surgery, The Hospital for Sick Children, 555 University Ave., Toronto ON M5G 1X8

© 1999 Canadian Medical Association (text and abstract/résumé)

pital for Sick Children in Toronto.

On examination, the boy was lethargic and had a temperature of 39.1 °C. His hip, held in slight flexion and external rotation, was extremely painful with any motion. Radiographs of the hip and pelvis revealed a small lytic area, possibly due to osteomyelitis, adjacent to the epiphyseal plate (Fig. 1). There was no evidence of a slipped epiphysis. His leukocyte count was $8.6 \times 10^9/L$ and the erythrocyte sedimentation rate was 123 mm/h. Ultrasonography of the hip showed an effusion with debris present in the joint. The presumptive diagnosis of septic arthritis of the hip was made.

Emergency incision and drainage of the right hip through an anterior approach revealed a large amount of pus. The articular cartilage of the femoral head and acetabulum was darkened in 50% of the surface area. A closed suction drain was placed in the hip, and the subcutaneous tissue and skin were closed. Within 24 hours, the boy's temperature returned to normal, his pain lessened and he was able

to bear weight on the affected leg. *Staphylococcus aureus* sensitive to cloxacillin was grown from a culture of hip tissue. The drain was removed on postoperative day 2. Cloxacillin was given intravenously for 6 days. He was then discharged home, bearing partial weight on the affected leg and was prescribed cloxacillin orally 1 g every 6 hours.

Two weeks later he returned to the outpatient clinic, complaining of increasing pain and inability to bear weight. There was a small amount of purulent drainage from the drain site. Radiographs of the hip revealed a slipped capital femoral epiphysis of the right hip with a slight relative increase in the density of the epiphysis (Fig. 2). A subcutaneous abscess was drained and he was given cloxacillin intravenously 1 g every 6 hours. Postoperatively, he was placed in skin traction. Six days later, he underwent percutaneous pinning of the slipped epiphysis in situ.

One week later (1 month after the initial operation) he was readmitted because of severe right hip pain. Radi-

ographs revealed obvious relative radiodensity of the capital epiphysis, indicating avascular necrosis of the femoral head (Fig. 3). He was given physical therapy, and when he was in bed the leg was placed in slings and allowed to swing free. The pain gradually diminished and he was discharged 10 days after admission.

Eleven months after the initial operation, the boy underwent removal of the pin because the tip of the screw was approaching the hip joint. Because of the avascular necrosis and associated growth arrest of the proximal femur, the patient had a length discrepancy of 2.5 cm. Two months later, he underwent a left distal femoral epiphysiodesis (performed under fluoroscopic guidance using a 4-mm Association for Osteosynthesis drill and a curette by way of medial and lateral incisions).

At follow-up, 2 years postoperatively, the boy was free of pain. He had a Trendelenberg lurch and a leg-length discrepancy of 2 cm. The range of motion of the right hip was 15° of adduction, no abduction, 35° of exter-

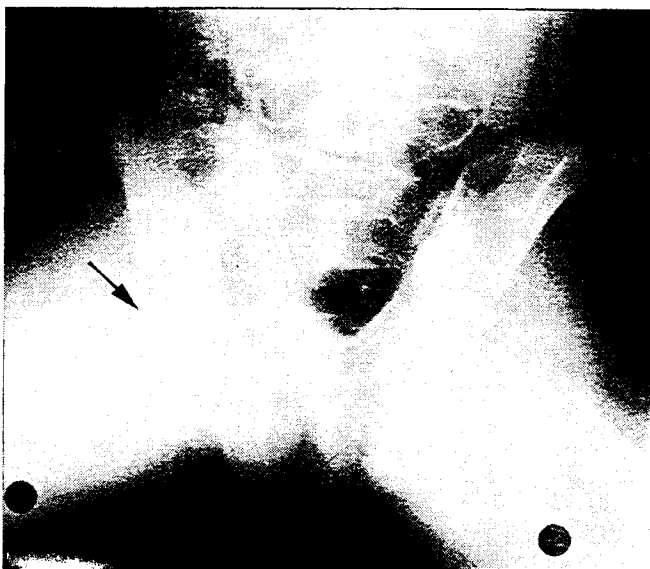

FIG. 1. Two weeks after the onset of pain, the radiograph shows no evidence of a slipped capital femoral epiphysis. There is an area of possible osteomyelitis adjacent to the epiphyseal plate (arrow).

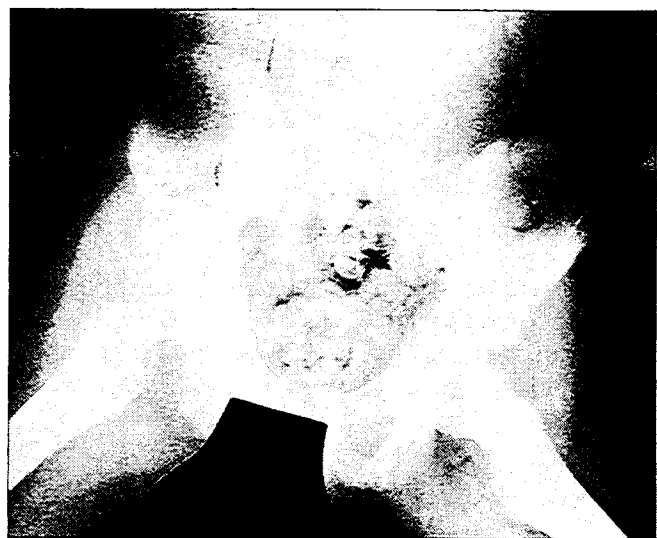

FIG. 2. Two weeks after incision and drainage of the hip, the radiograph shows a slipped capital femoral epiphysis of the right hip with a slight relative increase in the density of the epiphysis. There is also a slight decrease in the joint space compared with the contralateral side.

nal rotation, 5° of internal rotation and flexion from 20° to 90°. Radiographs showed avascular necrosis and collapse of the femoral head (Fig. 4).

DISCUSSION

Complications secondary to septic arthritis of the hip have become relatively less frequent since the advent of antibiotics and recognition of the importance of prompt surgical drainage. Although the potential complications of the delayed treatment are multiple,^{4,9,11} the 2 commonest complications are chondrolysis^{12,13} and avascular necrosis.¹⁴

In our case, in which an adolescent boy received delayed treatment for septic arthritis of the hip and later presented with a slipped capital femoral epiphysis, the coexistence of a slip and a septic arthritis may have been due to the delay in treating the infection and secondary damage to the growth plate with subsequent slip. Alternatively, the boy may have had an undisplaced slip at the time of the initial presenta-

tion, complicated by septic arthritis and subsequent worsening of the slip. The former cause is more likely for several reasons. First, slipped epiphysis is a known complication of septic arthritis and has been documented in younger children in the preantibiotic era^{6,7} and before urgent arthrotomy became the standard of care for septic hips.⁸⁻¹⁰ Second, a traumatic undisplaced slip of the femoral capital epiphysis in an otherwise healthy boy of normal weight is quite unusual. As noted in Fig. 1, there was no radiographic evidence of displacement of the capital femoral epiphysis when we first examined the hip. Third, the boy was able to continue playing hockey after the injury, which would be unlikely in the event of a traumatic slip.

Slipped capital femoral epiphysis secondary to delayed treatment of septic arthritis of the hip in an adolescent is previously unreported. The patient's height and weight were in the 70th percentile for his age so obesity was not a contributing factor in the slip. The infectious agent in this case was

S. aureus, the commonest infecting organism in septic arthritis² and a particularly virulent pathogen.⁴ It is possible that the prolonged delay before initiating therapy led to the destruction of the cartilage of the growth plate, resulting in the slip.

Chronic osteomyelitis and avascular necrosis of the femoral head has been treated by excision of the head,⁶ subtrochanteric osteotomy⁴ or simple drainage with spontaneous absorption of the head.^{6,9} When the boy in our case presented with a subcutaneous abscess and the slipped epiphysis, the preferred treatment was uncertain for several reasons. First, the femoral head may have been a sequestrum, which could have led to implant infection or failure of fixation had the fixation been undertaken at the time of the drainage procedure. Second, the optimal timing and indications for pin fixation of an infected slipped capital epiphysis are unknown.

Our management protocol for this condition was irrigation and débridement of the subcutaneous abscess, fol-

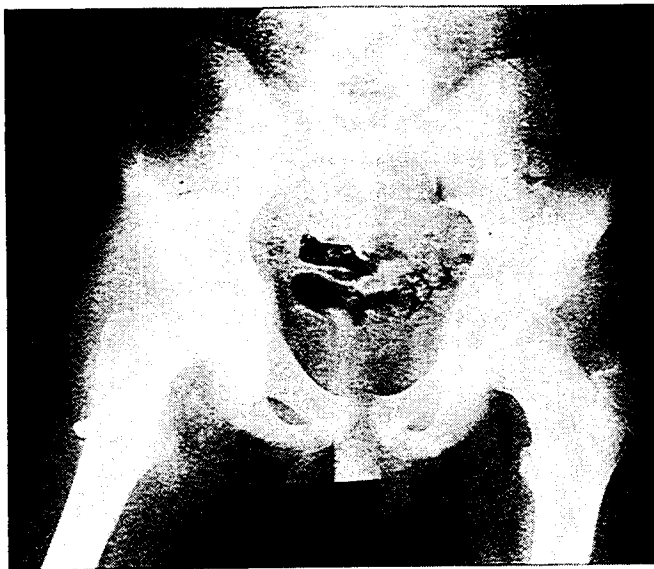


FIG. 3. One month after incision and drainage of the hip, and after pin fixation of the slipped capital femoral epiphysis, there is a relative increase in the radiodensity of the femoral head, indicating avascular necrosis. The joint space is significantly narrowed compared with the contralateral side.

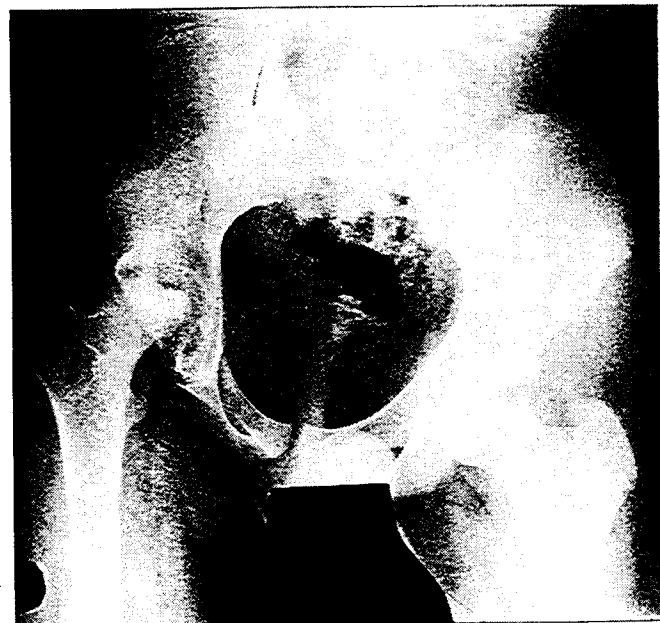


FIG. 4. Two years after the initial presentation, the radiograph shows avascular necrosis and collapse of the femoral head.

lowed by traction and delayed in-situ hip pinning. The rationale of the chosen treatment was to keep the hip anatomy as normal as possible. In our case, the boy did not suffer any of the potential infectious complications of this treatment and regained some pain-free motion of his hip joint at the 2-year follow-up. However, there remained a leg-length discrepancy and restricted motion at the hip, and he was left with a permanent disability.

Dr. Robert G. Marx is supported by the Arthritis Society, the Institute for Work and Health and the Surgical Scientist Program at the University of Toronto. Dr. James G. Wright is an MRC Scientist.

References

1. Daniel D, Akeson W, Amiel D, Ryder M, Boyer J. Lavage of septic joints in rabbits: effects of chondrolysis. *J Bone Joint Surg [Am]* 1976;58(3):393-5.
2. Gillespie R. Septic arthritis. *Clin Orthop* 1973;96:152-9.
3. Fabry G, Meire E. Septic arthritis of the hip in children: poor results after late and inadequate treatment. *J Pediatr Orthop* 1983;3:461-6.
4. Morrey BF, Bianco AJ, Rhodes KH. Suppurative arthritis of the hip in children. *J Bone Joint Surg [Am]* 1976;58:388-92.
5. Paterson DC. Acute suppurative arthritis in infancy and childhood. *J Bone Joint Surg [Br]* 1970;52(3):474-82.
6. Badgley CE, Yglesias L, Perham WS, et al. Study of the end results in 113 cases of septic hips. *J Bone Joint Surg* 1936;18(4):1047-61.
7. Green WT. Osteomyelitis in infancy. *JAMA* 1935;105(23):1835-9.
8. Blanche DW. Osteomyelitis in infants. *J Bone Joint Surg [Am]* 1952;34(1):71-85.
9. Eyre-Brook AL. Septic arthritis of the hip and osteomyelitis of the upper end of the femur in infants. *J Bone Joint Surg [Br]* 1960;42(1):11-20.
10. Lloyd-Roberts GC. Suppurative arthritis of infancy. *J Bone Joint Surg [Br]* 1960;42(4):706-20.
11. Stetson JW, DePonte RJ, Southwick WO. Acute septic arthritis of the hip in children. *Clin Orthop* 1968;56:105-16.
12. Curtiss PH, Klein L. Destruction of articular cartilage in septic arthritis; I. In vitro studies. *J Bone Joint Surg [Am]* 1963;45(4):797-806.
13. Curtiss PH, Klein L. Destruction of articular cartilage in septic arthritis; II. In vivo studies. *J Bone Joint Surg [Am]* 1965;47(8):1595-604.
14. Kemp HBS, Lloyd-Roberts GC. Avascular necrosis of the capital epiphysis following osteomyelitis of the proximal femoral metaphysis. *J Bone Joint Surg [Br]* 1974;56(4):688-97.